

National Athletic Trainers' Association Position Statement: Acute Management of the Cervical Spine—Injured Athlete

Erik E. Swartz, PhD, ATC*; Barry P. Boden, MD†; Ronald W. Courson, ATC, PT, NREMT-1, CSCS‡; Laura C. Decoster, ATC§; MaryBeth Horodyski, EdD, ATC||; Susan A. Norkus, PhD, ATC¶; Robb S. Rehberg, PhD, ATC, CSCS, NREMT#; Kevin N. Waninger, MD, MS, FAAFP, FACSM**

*University of New Hampshire, Durham, NH; †Uniformed Services University of the Health Sciences, Bethesda, MD, and The Orthopaedic Center, PA, Bethesda, MD; ‡University of Georgia Athletic Association, Athens, GA; §New Hampshire Musculoskeletal Institute, Manchester, NH; ||University of Florida, Gainesville, FL; ¶Quinnipiac University, Hamden, CT; William Paterson University, Wayne, NJ; **St Luke's Hospital, Bethlehem, PA

Objective: To provide certified athletic trainers, team physicians, emergency responders, and other health care professionals with recommendations on how to best manage a catastrophic cervical spine injury in the athlete.

Background: The relative incidence of catastrophic cervical spine injury in sports is low compared with other injuries. However, cervical spine injuries necessitate delicate and precise management, often involving the combined efforts of a variety of health care providers. The outcome of a catastrophic cervical spine injury depends on the efficiency of this management process and the timeliness of transfer to a controlled environment for diagnosis and treatment.

Recommendations: Recommendations are based on current evidence pertaining to prevention strategies to reduce the incidence of cervical spine injuries in sport; emergency planning and preparation to increase management efficiency; maintaining or creating neutral alignment in the cervical spine; accessing and maintaining the airway; stabilizing and transferring the athlete with a suspected cervical spine injury; managing the athlete participating in an equipment-laden sport, such as football, hockey, or lacrosse; and considerations in the emergency department.

Key Words: catastrophic injuries, emergency medicine, neurologic outcomes

The incidence of spinal cord injury in the United States is estimated to include 11 000 new cases each year.¹ Serious spinal injuries have devastating sequelae, including neurologic impairment and premature mortality. Sport participation constitutes the fourth most common cause (approximately 7.4%)¹ of these injuries overall but is the second most common cause for those younger than 30 years of age.² Since 2000, the majority of all cervical spine injuries have occurred in individuals between the ages of 16 and 30 years.¹

American football in the United States is associated with the greatest number of catastrophic spinal injuries for all US sports.³ Although catastrophic cervical spine injuries have decreased compared with the incidence in the early 1970s, an average of 7.8 catastrophic cervical spine injuries with incomplete recovery⁴ and 6 quadriplegic events⁵ occurred annually in football alone (data from 1997–2006). Of particular concern is a recent trend of double-digit catastrophic spine injuries in 3 of the 4 years between 2003 and 2006; from 1991 to 2002, only data from 1999 showed catastrophic spine injuries measuring in the double digits.⁶

Epidemiologic data have established the risk of catastrophic cervical spine injury in other sports as well. For example, an average of 15 catastrophic spine injuries occur annually in ice hockey in Canada and the United States.⁷

Sports such as skiing,^{8–13} rugby,^{14–17} gymnastics,^{18,19} swimming and diving,^{20,21} track and field (eg, pole vaulting),²² cheerleading,²³ and baseball²⁴ all involve activities that place participants at risk for spine injuries. In fact, the incidence of nonfatal, direct catastrophic injuries in the sports of lacrosse, gymnastics, and men's ice hockey is higher than that in American football (Table 1).³

Regardless of the sport, proper management and accurate diagnosis of acute spinal injuries are paramount because of the recognized risk of neurologic deterioration during and after the initial management of the injury.^{25,26} Consequently, sports medicine providers must be familiar with the appropriate acute management guidelines for the cervical spine-injured athlete.

PURPOSE

The purpose of this position statement is to provide athletic trainers, team physicians, emergency responders, and other health care professionals with recommendations and clinical considerations for managing a major,²⁷ potentially catastrophic^{28,29} cervical spine injury. A *catastrophic cervical spine injury* is defined as “a structural distortion of the cervical spinal column associated with actual or potential damage to the spinal cord.”²⁸

Table 1. Combined High School and College Catastrophic Injury Data in Select Sports Derived From the National Center for Catastrophic Sport Injury Research, Fall 1982 Through Spring 2007^{3,a}

Sport	Setting	Direct Catastrophic Injuries	Direct Injury Incidence Rates (Nonfatal ^b) per 100 000 Population	
			Males	Females
American football (males)	High school	603	0.75	NA
	College	133	1.89	
Gymnastics	High school	13	2.08	0.97
	College	6	20.07	5.35
Ice hockey	High school	19	1.02	0.00
	College	12	4.18	0.00
Track and field	High school	59	0.12	0.01
	College	10	0.34	0.15
Lacrosse	High school	9	0.52	0.00
	College	11	2.11	2.01
Wrestling (males)	High school	58	0.60	NA
	College	1	0.00	NA
Cheerleading	High school	46
	College	23

Abbreviations: NA, not applicable; ..., data not available.

^a Data reprinted with permission of the National Center for Catastrophic Sport Injury Research.

^b Nonfatal indicates permanent severe disability.

Specifically, this statement will provide recommendations based on current, rated evidence (Table 2) pertaining to the following:

1. Prevention strategies to reduce the incidence of cervical spine injuries in sport,
2. Emergency planning and preparation to increase management efficiency,
3. Maintaining or creating neutral alignment in the cervical spine,
4. Accessing and maintaining the airway,
5. Stabilizing and transferring an athlete with a suspected cervical spine injury,
6. Equipment-related issues in sports such as football, hockey, and lacrosse,
7. Imaging and diagnostic considerations in the emergency department, and
8. The role of hypothermia treatment and high-dose corticosteroids in the acute management of the cervical spine-injured athlete.

RECOMMENDATIONS

Based on current research and expert consensus related to cervical spine injury, the National Athletic Trainers'

Association provides the following recommendations for prevention and emergency management of the athlete with a suspected catastrophic cervical spine injury.

Prevention

1. Individuals responsible for the emergency care of athletes should be familiar with sport-specific causes of catastrophic cervical spine injury and understand the acute physiologic response of the spinal cord to injury. *Evidence Category: C*
2. Those responsible for the emergency care of athletes should be familiar with safety rules enacted for the prevention of cervical spine injuries and should take actions to ensure that such rules are followed. *Evidence Category: C*
3. Persons responsible for the emergency care of athletes should be familiar with pertinent protective equipment manufacturers' recommendations and specifications relative to fit and maintenance. Maintaining the integrity of protective equipment helps to minimize the risk of injury. *Evidence Category: C*
4. Individuals responsible for the emergency care of athletes should educate coaches and athletes about the mechanisms of catastrophic spine injuries, the dangers

Table 2. Strength of Recommendation Taxonomy^a

Strength of Recommendation	Definition
Patient-oriented evidence	
A	Recommendation based upon consistent and good-quality patient-oriented evidence (morbidity, mortality, symptom improvement, cost reduction, and quality of life)
B	Recommendation based on inconsistent or limited-quality patient-oriented evidence
C	Recommendation based on consensus, usual practice, opinion, disease-oriented evidence (measures of intermediate, physiologic, or surrogate end points that may or may not reflect improvements in patient outcomes), or case series for studies of diagnosis, treatment, prevention, or screening

^a Adapted or reprinted with permission from "Strength of Recommendation Taxonomy (SORT)," March 1, 2008, American Family Physician. Copyright 2008 American Academy of Family Physicians. All Rights Reserved.

of head-down contact, and pertinent safety rules enacted for the prevention of cervical spine injuries.³⁰
Evidence Category: C

Planning and Rehearsal

5. Those responsible for the care of athletes should be familiar with the National Athletic Trainers' Association position statement on emergency planning in athletics.³¹ *Evidence Category: C*
6. Planning in advance of events carrying a risk of cervical spine injury should include preparation of a venue-specific emergency action plan. Components of the emergency action plan include appointing a team leader and acquiring appropriate equipment to facilitate stabilization, immobilization, and removal of treatment barriers (ie, sporting equipment). The emergency action plan should also incorporate communication with local emergency medical services and identification of the most appropriate emergency care facility to receive the injured athlete. These groups should be involved in creating the emergency action plan.³¹ *Evidence Category: C*
7. All individuals responsible for the care of athletes should be involved in regular (at least annual) rehearsals of the emergency action plan, as well as training and practice in the special skills inherent to managing a cervical spine injury. Skills requiring training and regular practice may include manual head and neck stabilization techniques, the multiple methods of transferring injured athletes (eg, log-rolling, lift-and-slide techniques), equipment management (eg, gaining access to the airway or chest), and immobilization methods (eg, long spine board, cervical collar application).³¹ *Evidence Category: C*

Assessment

8. During initial assessment, the presence of any of the following findings, alone or in combination, heightens the suspicion for a potentially catastrophic cervical spine injury and requires the initiation of the spine injury management protocol: unconsciousness or altered level of consciousness, bilateral neurologic findings or complaints, significant midline spine pain with or without palpation, and obvious spinal column deformity.^{32–37} *Evidence Category: A*

Stabilization

9. When a potential spine injury is suspected, rescuers should ensure that the cervical spine is in a neutral position and should immediately apply manual cervical spine stabilization. This will minimize motion during the management of the injury.^{38–42} *Evidence Category: B*

10. Rescuers should not apply traction to the cervical spine, as this may cause distraction at the site of injury. Traction in a cervical spine with ligamentous injury can result in excessive distraction and subluxation that can further compromise the spinal cord.^{39–41,43–46} *Evidence Category: B*
11. If the spine is not in a neutral position, rescuers should realign the cervical spine to minimize secondary injury to the spinal cord and to allow for optimal airway management. However, the presence or development of any of the following, alone or in combination, represents a contraindication for moving the cervical spine to neutral position^{40,41}: the movement causes increased pain, neurologic symptoms, muscle spasm, or airway compromise; it is physically difficult to reposition the spine; resistance is encountered during the attempt at realignment; or the patient expresses apprehension.^{32,47–54} *Evidence Category: B*

Airway

12. Rescuers should immediately attempt to expose the airway, removing any existing barriers (eg, protective face masks). *Evidence Category: C*
13. If rescue breathing becomes necessary, the individual with the most training and experience should establish an airway and commence rescue breathing using the safest technique.^{55–57} *Evidence Category: B*
14. During airway management, rescuers should cause as little motion as possible.^{39,58} *Evidence Category: C*
15. The jaw-thrust maneuver is recommended over the head-tilt technique, which produces unnecessary motion at the head and in the cervical spine. Advanced airway management techniques (eg, laryngoscope, endotracheal tube) are recommended in the presence of appropriately trained and certified rescuers; these methods have been shown to cause less motion and, therefore, are less likely to worsen neurologic status.^{55,59–65} *Evidence Category: B*

Transfer and Immobilization

16. Manual stabilization of the head should be converted to immobilization using a combination of external devices (eg, cervical collars, foam blocks), and stabilization of the cervical spine should be continued until a destabilizing injury has been ruled out using appropriate diagnostic testing (imaging). Whenever possible, manual stabilization should be resumed^{65,66} after the application of external devices.^{40,67–70} *Evidence Category: B*
17. Individuals responsible for the emergency care of athletes with cervical spine injuries should be prepared to immobilize these athletes with a long spine board or other full-body immobilization device.^{57,67,69,71} *Evidence Category: B*

18. Although the traditional spine board represents the most common device used for full-body immobilization, devices such as the full-body vacuum splint are more comfortable for athletes, reduce superficial irritation and sores over bony prominences, and may be used in appropriate situations.^{57,69,71} *Evidence Category: B*
19. For the supine athlete, a lift-and-slide technique (eg, 6-plus-person lift, straddle lift and slide) of transferring the athlete to an immobilization device has been reported to produce less motion at the head and in the cervical spine than the log-roll technique and should be used in appropriate situations.^{72–75} *Evidence Category: B*
20. For the prone athlete, all potential rescuers must be familiar with the log-roll method of transferring to an immobilization device. *Evidence Category: C*
24. If the athletic helmet is dislodged during the injury or removed (by either the medical team or the athlete) or if the shoulder pads cannot be easily removed, care must be taken to place padding beneath the head to maintain neutral cervical spine alignment. *Evidence Category: C*
25. A rigid cervical immobilization collar should be placed on the athlete before transfer to a spine board. In equipment-laden sports, this may be difficult or impossible, although a cervical vacuum immobilization device has been shown to limit cervical spine range of motion in the fully equipped football player.⁸¹ *Evidence Category: C*
26. Individuals responsible for the emergency care of athletes in equipment-laden sports should be familiar with their team's equipment (external defibrillators) and the tools and techniques required for removal of barriers to treatment (eg, airway management). *Evidence Category: C*

Equipment-Laden Athletes

21. Because removal of athletic equipment such as helmet and shoulder pads may cause unwanted movement of the cervical spine, removal of helmet and shoulder pads should be deferred until the athlete has been transported to an emergency medical facility, except under specifically appropriate circumstances. The first exception is if the helmet is not properly fitted to prevent movement of the head independent of the helmet. This is imperative, because when the helmet is left in place, it is responsible for securing the head, and, as such, immobilization of the helmet necessarily results in immobilization of the head. The second exception is if the equipment prevents neutral alignment of the cervical spine or airway access. This exception is further addressed in the following recommendations.^{76,77} *Evidence Category: B*
22. Independent removal of the helmet or shoulder pads in American football and ice hockey is not recommended, because removing one and not the other compromises spinal alignment. Removal of the helmet and shoulder pads in these sports should be considered an all-or-nothing endeavor.^{54,76–78} *Evidence Category: B*
23. No general recommendation regarding removal of equipment can be made for other sports that require a helmet (with or without shoulder pads) because of considerable variation in the capacity of that equipment to maintain a neutral cervical spine or immobilize the head. The primary acute treatment goals in these sports are to ensure that the cervical spine is properly aligned and that the head and neck are immobilized. Upon observation, if the equipment being worn does not permit the cervical spine to rest in neutral or does not adequately immobilize the head, then removal of one or more pieces of equipment in a safe manner is advisable to achieve neutral alignment or adequate stabilization (or both).^{79,80} *Evidence Category: C*
27. Face masks that interfere with the ability to access the airway should be completely removed from the helmet. *Evidence Category: C*
28. Face-mask removal should be initiated once the decision to immobilize and transport has been made. *Evidence Category: C*
29. Rescuers should be aware of, and well trained in, established face-mask removal techniques. The face mask should be removed with the tool and technique that perform the task quickly and with minimal movement and difficulty. A powered (cordless) screwdriver is generally faster, produces less head movement, and is easier to use than cutting tools; it should be the first tool used in attempting to remove a face mask attached with loop straps that are secured with screws. Because it may be impossible to remove the screws, a backup cutting tool, specifically matched to the sport equipment used, should be available. This is referred to as a *combined-tool approach*.^{82–87} *Evidence Category: B*
30. To increase the likelihood that all 4 screws can be successfully removed from a football helmet face mask using a cordless screwdriver, athletic trainers, coaches, and equipment managers should ensure that corrosion-resistant hardware is used in the helmet, that helmets are regularly maintained throughout a season, and that helmets undergo regular reconditioning and recertification.^{82,85} *Evidence Category: B*
31. If the face mask cannot be removed in a reasonable amount of time, then the helmet should be removed from the athlete in the safest manner possible. Helmet style will dictate the technique necessary to safely remove the helmet. A neutral cervical spine position should be preserved during and after this process by removing additional pieces of equipment (eg, shoulder pads) or by placing an object underneath the head (eg, towel, padding) to maintain neutral alignment. *Evidence Category: C*

Emergency Department Management

32. If possible, the team physician or certified athletic trainer should accompany the athlete to the hospital. This provides continuity of care, allows for accurate delivery of clinical information to the emergency department staff, and may allow the sports medicine professional to assist emergency department personnel during equipment removal. *Evidence Category: C*
33. Remaining protective equipment should be removed by appropriately trained professionals in the emergency department environment. Emergency department personnel should make an effort to become familiar with proper athletic equipment removal, seeking education from sports medicine professionals regarding appropriate methods to minimize motion.^{76,77,88} *Evidence Category: C*
34. Emergency departments should consider implementing guidelines for the use of computed tomography (CT) rather than plain radiographs as the primary diagnostic test for a suspected cervical spine injury in a helmeted athlete. Obtaining plain radiographs adequate for clearance with sport equipment in place is a procedure unsupported by research. A CT may be more sensitive than plain radiographs and is associated with lower rates of missed primary and secondary injuries.^{89–94} *Evidence Category: B*
35. Emergency department personnel should be aware that magnetic resonance imaging (MRI) is clinically limited for helmeted athletes and may not be suitable as an initial diagnostic tool.⁹⁵ *Evidence Category: B*

The Role of Hypothermia Treatment and High-Dose Corticosteroids in the Acute Management of an Athlete With Cervical Spine Injury

36. Although the role of hypothermia in the treatment of myocardial infarction and brain injury has been investigated and has shown potential to reduce morbidity, evidence is currently insufficient to justify its use in the acute management of the spine-injured athlete.^{96,97} *Evidence Category: C*
37. High-dose methylprednisolone for acute spinal cord injury has been used in the initial management of acute spinal cord injury; however, this practice has recently been questioned. One evidence-based analysis of the published literature on methylprednisolone revealed serious flaws in data analysis and conclusions, with no clear support for the use of methylprednisolone in patients with acute spinal cord injury.⁹⁸ Until additional reliable data are available, the use of high-dose methylprednisolone in this instance remains controversial. When possible, each patient or patient's family should be informed of the risks and benefits of the medication before use. *Evidence Category: B*

CLINICAL CONSIDERATIONS

Based on expert consensus and current research, the National Athletic Trainers' Association provides the following special clinical considerations for emergency management of the athlete with a suspected cervical spine injury.

Transfer and Immobilization (Appendix A: Figures 1–5)

1. A variety of techniques exist to transfer and immobilize the injured athlete. Rescuers should use the technique that they have reviewed and rehearsed and that produces the least amount of spinal movement.
2. To facilitate transfer, the patient's body should be aligned as carefully as possible. Arms should be carefully moved to the sides and legs straightened and positioned together.
3. If the athlete is prone, rescuers should inspect the spine before moving him or her.
4. If it is necessary to reposition the patient once on the spine board, he or she should not be moved in a perpendicular direction, to avoid shearing and the possibility of spinal column movement. Instead, the patient should be moved in either a cephalad or caudad direction, as deemed necessary by the rescuer controlling the head and neck.
5. Selection of appropriate transfer and spine boarding techniques
 - a. The log-roll technique requires 4 to 5 rescuers: 1 to control the head and cervical spine, 2 to 3 to roll the patient on command, and 1 to position the spine board.
 - b. Lift-and-slide technique
 - i. The 6-plus-person lift involves lifting the athlete to allow for spine board placement. This technique is effective in minimizing structural interference that could result in unwanted spinal column movements.
 - ii. The straddle lift-and-slide technique requires only 4 rescuers to lift the body.
 - c. For the supine athlete, the log-roll or lift-and-slide techniques may be used; for a prone athlete, the log-roll technique is the only option. Therefore, all rescuers must be familiar with the log roll.
6. Equipment recommendations for spine boarding
 - a. A scoop stretcher with telescoping arms that is hinged on both ends may be used to "scoop" the athlete without having to perform the log roll or lift and slide; however, the device may only be used in this manner if the athlete is in the supine position.
 - b. Vacuum immobilization creates a custom form-fit, full-body splint and has been found to be more comfortable for patients than a standard spine board.^{57,71} This option may be used on either a supine or a prone athlete, but it may be better suited for the lift-and-slide technique because of its semirigid structure. The large size, however, may

make it difficult to slide between the rescuers on either side.

- c. A short-board system may be useful in immobilizing seated athletes; those with a flexed trunk or awkward positioning; and those affected by equipment barriers, such as the gymnastics or pole-vault pit.

7. Head immobilization

- a. The head should always be the last part of the body secured to the spine board.
- b. A variety of head-immobilization options exist, including commercial head-immobilization devices, contoured helmet blocks, foam blocks, and towel rolls. Sand bags are not recommended as head-immobilization devices, as their weight is a liability during transfer.
- c. Once the selected head-immobilization device is placed to stabilize the head, tape or hook-and-loop straps should be used to secure the head to the spine board using 2 separate points of contact, the chin and the forehead,⁷⁸ to prevent as much head and neck motion as possible.

- 8. A spine board kit should contain all necessary packaging supplies: head-immobilization device, cervical collar, face-mask-removal tools, straps to secure the athlete to the board, wrist straps to secure the athlete's hands together, tape, and various sizes of padding or toweling.
- 9. Rescuers should select the strapping technique with which they are most comfortable and skilled.
- 10. When securing the athlete to the spine board, the arms should be kept free to facilitate a variety of diagnostic and treatment techniques.
- 11. Once the torso is secured to the spine board, the hands may be secured together on top of the body using hook-and-loop wrist straps or tape.
- 12. The athlete should be restrained and secured sufficiently to the spine board that the board may be turned without creating spinal movement, in case, for example, the athlete vomits.
- 13. Some athletes with cervical spine injuries may have concurrent closed head injuries. Therefore, rescuers may encounter combative athletes who resist immobilization. The rescuers should attempt to calm the patient and minimize movement as much as possible based upon the individual circumstances.
- 14. The ambulance should be positioned as close to the scene as possible to minimize transfer on a stretcher over surfaces that may cause body movement.

Equipment-Laden Athletes (Appendix B: Figures 6–9)

15. Face-mask removal

- a. Removing the loop straps from face masks can be a difficult skill and requires extensive practice.

- b. For a football helmet face mask with 4 attachment locations, the 2 side straps should be removed first, followed by the top straps. This prevents the face mask from rotating down onto the athlete's face or throat during the removal attempt.

- c. Placing pressure on the underside of the loop strap with the thumb of the other hand while unscrewing can assist in separating the screw from the T-nut.
- d. If, when attempting to remove the screws from the helmet, 1 or more screws cannot be removed, it is important to continue with the next screw until all screws that can be unscrewed are successfully removed.
- e. If a backup cutting tool is required, ensure that the tool chosen will successfully cut the loop straps currently being used in the helmets worn by the football team or teams being covered. Not all face-mask removal tools will remove all helmet-loop strap combinations.⁸⁶
- f. A screwdriver may not suffice as a backup tool for loop straps secured with a quick-release mechanism rather than a traditional screw and T-nut attachment system. Therefore, an appropriate backup tool should be available to cut away the loop strap should the quick-release system fail.

- 16. Because individual circumstances may dictate removal of an athletic helmet or shoulder pads, athletic trainers and emergency responders should be trained in helmet and shoulder-pad removal. This skill should be rehearsed on a regular basis with the specific equipment used by that team, organization, or facility. Emergency department personnel should also be trained in athletic helmet and shoulder-pad removal.

THE EVIDENCE: BACKGROUND AND LITERATURE REVIEW

The evidence to support the above-listed recommendations follows. However, we should note that every emergency situation and every patient are unique and that individual circumstances must dictate appropriate actions. Furthermore, the recommendations listed above related to spine-injury management skills and techniques tend to be based on research results that yielded the least amount of motion at the head and neck or the most optimal position for the spinal cord. Yet, how much motion or how far from neutral alignment would result in further injury during spine-injury management is unknown. Because the “safe” amount of motion and degree of alignment are not known, and because the extent of injury in the prehospital stage is not known, we must strive to create as little motion as possible and to ensure an optimal position for the spinal cord within the spinal canal (ie, neutral alignment of the spinal column).

Prevention

Pathomechanics of Catastrophic Cervical Spine Injury. The highest number of catastrophic cervical spine injuries in the United States occurs in the sport of American football,^{29,99} and the most common injury mechanism

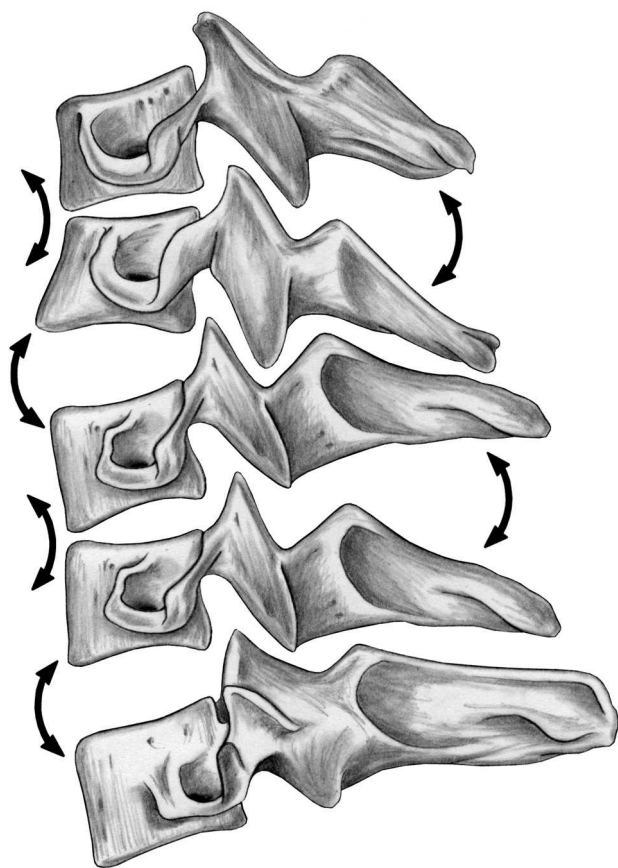


Figure 10. Buckling effect in the cervical column under axial load. Reprinted with permission from Swartz EE, Floyd RT, Cendoma M. Cervical spine functional anatomy and the biomechanics of injury due to compressive loading. *J Athl Train.* 2005;40(3):155–161.

occurs during tackling when the top of the head is used as the point of contact.^{5,29,30} This mechanism is referred to as an *axial load*, which can occur in any sport. During axial loading, compressive forces create a buckling effect in the cervical spine.¹⁰⁰ This buckling produces large angulations within the cervical spine as a means of releasing the additional strain energy produced by the vertical loading, and this buckling is the causative factor of injury^{100–102} (Figure 10). This unique buckling effect of the cervical vertebrae, partially explained through the work of Penning¹⁰³ and Amevo et al,¹⁰⁴ is linked to the location of a vertebra's instantaneous center of rotation (ICR). The center of rotation for a particular vertebra is located near the superior aspect of the inferiorly adjacent vertebral body. As the lines of force are transmitted down the cervical column, the vertebra experiences flexion or extension, depending on the location of the force vector relative to the ICR. Hence, if the cervical column is moving into flexion, but the relative orientation of one vertebra to the other causes the force vector to pass behind the ICR, then that vertebra extends^{103,104} (Figure 11).

The resultant injury (or injuries) depends on many factors but may be influenced by the velocity of the applied load,^{102,105} the point of contact on the head relative to the axis of the cervical spine,^{100,101} the resultant mode of buckling,^{100,101} and the type of surface with which the head came into contact (ie, solid versus padded).¹⁰⁶ A critical

factor contributing to the degree of neurologic injury is the extent to which the injury involves the spinal cord. During axial compression or extreme ranges of motion in the cervical spine, the spinal canal experiences transient geometric changes in diameter and height, which may eliminate the space surrounding the spinal cord, potentially resulting in neural tissue damage.^{47,107} Even if the spinal cord survives insult during the initial injury, its integrity may still be threatened if the osseous and soft tissue structures were injured sufficiently to create instability in the cervical spine.²⁷

Acute Physiologic Response. Although most sport injuries do not result in complete transection of the cord,¹⁰⁸ complete sensory and motor loss can still occur. The outcome largely depends on the degree and duration of trauma. The histologic response within the spinal cord involves both primary injury and a secondary injury response that can lead to destruction of the neural tissue.

Spinal nerve destruction is attributed to both an acute vasospasm within the capillary network and edema-causing traumatic hemorrhagic necrosis within the protective layers of the cord.¹⁰⁹ This primary response contributes to decreased spinal cord perfusion. Capillary blood flow is disrupted after rupture of the intramedullary spinal blood vessels, resulting in gray matter hemorrhage. A build-up of cytotoxic amounts of extracellular calcium and release of norepinephrine from protective storage provoke cytotoxic responses within neurons.¹¹⁰ Sodium-potassium pump disruption and subsequent cellular membrane breakdown and lipid peroxidation contribute to neuron hydrolysis at the injury site.¹¹¹ The sodium-potassium pump is a vital component in the cell's ability to repolarize, and cellular membrane destruction allows for the influx of extracellular calcium, which becomes cytotoxic to the cell.¹¹¹ The gray matter undergoes progressive dissolution before the white matter.¹⁰⁹ These early changes in the injured spinal cord take place within the first 2 hours after trauma.¹¹¹

Equipment Maintenance. The National Operating Committee on Standards in Athletic Equipment (NOCSAE) was established in 1969 to research injury-reduction strategies in sports.¹¹² Since that time, NOCSAE has been recognized as the authority in equipment standards and the development of rules for many sport governing bodies. For example, the National Collegiate Athletic Association requires the use of NOCSAE-certified athletic equipment.¹¹³ The NOCSAE standards ensure that a helmet is able to withstand a certain degree of impact, and recertification confirms that used helmets do not fall below NOCSAE standards.¹¹⁴ Alterations (for example, the drilling of holes through the helmet shell or the use of inappropriate or unapproved hardware) may affect the helmet's effectiveness.¹¹⁴ Adherence to standards concerning the helmet shell and hardware affords sports medicine personnel a reasonable degree of assurance that the variety of equipment they may need to remove in an emergency will be somewhat limited.

Current recommendations leave the frequency of helmet recertification to the discretion of the user. Swartz et al⁸⁵ demonstrated increasing difficulty with face-mask removal as the time from last recertification increased. Therefore, it appears that more regular reconditioning, including replacement of all metal hardware, would reduce the

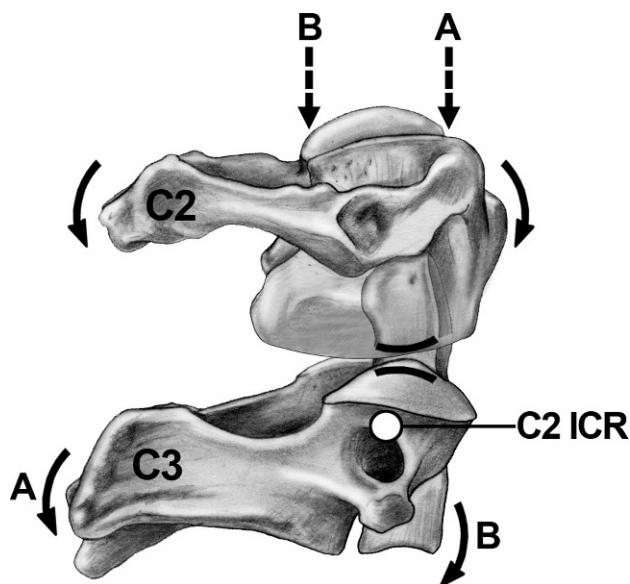


Figure 11. The instantaneous center of rotation (ICR) for a vertebra is located near the superior aspect of the inferior vertebral body. The inferior vertebra's motion depends on the location of the force vector relative to the ICR. A, Hence, if the lines of force are transmitted anterior to the ICR, the inferior vertebra extends. B, If the lines of force are transmitted posterior to the ICR, the inferior vertebra flexes. Reprinted with permission from Swartz EE, Floyd RT, Cendoma M. Cervical spine functional anatomy and the biomechanics of injury due to compressive loading. *J Athl Train.* 2005;40(3):155–161.

likelihood of face-mask removal failure during an emergency. The use of corrosion-resistant metal screws also increases the probability of face-mask removal success.⁸⁵ Regular maintenance and inspection of helmets during a season can reduce the likelihood that a rescuer will encounter impediments to successful face-mask removal.⁸⁵ One example is the presence of foreign substances embedded in the loop-strap screw heads, such as dirt or plastic from other helmets, which prevents the insertion of the screwdriver into the screw head. Finally, certified athletic trainers should be familiar with equipment standards for the sport or sports with which they work, so they can better recognize and correct potential safety issues.

Education and Rules. Continuing education of certified athletic trainers, coaches, officials, and athletes to ensure understanding of injury mechanisms may reduce the risk of catastrophic injuries. Accepting responsibility for teaching (eg, athletic trainers and coaches), legislating (eg, governing bodies), implementing (eg, athletic trainers, coaches, and athletes), and enforcing (eg, officials) safe alternatives to dangerous activities is crucial. For example, axial loading of the cervical spine is responsible for most quadriplegic cervical injuries in football^{115,116} and hockey.^{116,117} Understanding this concept served as a springboard for rule changes and education that subsequently reduced the incidence of such injuries. The best examples of the effectiveness of this approach are the reduction in cervical spine quadriplegic injuries associated with the banning of spear tackling in football^{115,118} and hitting from behind (boarding) in ice hockey.¹¹⁷ Educational multimedia, such as the *Heads Up: Reducing the Risk of Head Injuries* in

Football DVD from the National Athletic Trainers' Association (<http://www.nata.org/consumer/headsup.html>), are available to achieve this purpose.

Planning and Rehearsal

The effect of creating or rehearsing an emergency plan, or specific skills within an emergency plan, on managing a catastrophic cervical spine injury is not well documented. Previous recommendations to incorporate planning and rehearsal of an emergency action plan appear to be based on expert consensus.^{31,119,120} Many individuals responsible for the care of athletes with catastrophic cervical spine injuries have already received skills training in on-field techniques as a result of requirements or educational competencies included in obtaining a degree, certification, or license to practice (eg, certified athletic trainer, emergency medical technician, physician). Additionally, many authors investigating or comparing spine-injury management skills require participants to be thoroughly trained and familiar with the procedures before data are collected and analyzed.^{72,75,86,121}

One group⁷³ analyzed the effect of additional training on the performance of transfer skills to an immobilization device and found no differences in proficiency between trained and untrained participants. In contrast, researchers in related fields have reported the beneficial effects of formal education¹²² and training¹²³ on specific medical skills.

Although the recommendation to create and rehearse an emergency action plan and the skills contained within it is logical from the medical and legal perspectives, the beneficial effects of the rehearsal of the emergency plan or its skills are not established in the literature. No minimum quantity or frequency of rehearsal sessions or type of training can be endorsed.

Assessment

During the initial assessment of an injured athlete suspected of having a potentially catastrophic cervical spine injury, the presence of any or all of the following 4 clinical indicators warrants the activation of the spine-injury management protocol: unconsciousness or altered level of consciousness, bilateral neurologic findings or complaints, significant cervical spine pain with or without palpation, and obvious spinal column deformity. In the presence of any of these findings, the use of spinal injury precautions in the athletic setting have been recommended.^{33,39,58,119} However, these recommendations are largely based on evidence from research in prehospital and emergency medicine settings rather than athletic settings.

Results from recent research in prehospital and emergency medicine studies have been used to develop and validate criteria for determining selective immobilization and spine clearance protocols in the prehospital setting.^{34–36,124,125} The most common criteria leading to immobilization in the prehospital setting include unconsciousness, altered mental status, evidence of intoxication, neurologic deficit, long-bone extremity fracture, or cervical, thoracic, or lumbar spine pain.^{34,35} Domeier et al³⁵ reported that most spine-injured patients (87%) included in a large prospective study presented with more than 1 of the measured clinical findings. The Glasgow Coma Scale has also been identified as a predictor of possible cervical spine

injury.^{36,126} Holly et al³⁶ noted that patients with an initial Glasgow Coma Scale score of 8 or less were more likely to have sustained a cervical injury than those with a score higher than 8. Further, Demetriades et al¹²⁶ identified an inverse relationship by which a lower Glasgow Coma Scale score correlates with a higher risk of cervical spine injury.

Holly et al³⁶ and Ross et al¹²⁷ have suggested a link among unconsciousness, mental status, and the possibility of cervical spine injury in trauma patients. Approximately 5% to 7% of patients presenting with unconsciousness and altered mental status had a spinal injury.^{36,127} In a prospective study of emergency medical services patient charts by Domeier et al,³⁴ 37% of spine-injured patients presented with altered mental status. Iida et al³⁷ reported that one-third of all spine-injured patients studied also sustained moderate or severe head injuries. It is important to note, however, that these studies involved mechanisms of injury that included high-velocity impacts (eg, falls, motor vehicle accidents) and were not limited to athletic participation.

Bilateral neurologic findings or complaints, altered mental status, significant midline pain, or obvious spinal column deformity, alone or in any combination, are indicators of potential cervical spine injury and warrant the use of spinal precautions. These criteria are extracted from validated prehospital and emergency medicine spinal clearance protocols, but on a case-by-case basis, other individual or collective signs or symptoms may indicate the presence of a cervical spine injury.

Stabilization

Manual cervical immobilization should be implemented as soon as possible once a cervical spine injury is suspected. The head should be manually stabilized by grasping the mastoid processes bilaterally with the fingertips while cupping the occiput in the hands.⁴⁶ The rescuer should position his or her hands so the thumbs are pointed toward the face of the injured athlete. This technique ensures that hand placement does not have to be changed with repositioning of the athlete, unless rolling the athlete from a prone to a supine position is required, in which case the rescuer's arms should be crossed before rolling. If the rescuer is alone, it may be appropriate to use the knees to maintain spine stabilization, thus freeing the rescuer's hands to assist with ventilation or to conduct further tests.

Traction. Rescuers should not apply traction forces to the head of the spine-injured athlete during stabilization and immobilization. Multiple authors^{39–41,44} have recommended against the application of traction during manual in-line stabilization, as movement of the unstable cervical spine may cause further injury. Cadaver-based studies and research investigating spine motion during orotracheal intubation in patients with ligamentous instability demonstrated that traction forces applied during manual in-line immobilization created distraction^{43,45,46} and posterior subluxation⁴³ at the site of injury.

Neutral Alignment of the Head and Neck. Medical professionals accept that the cervical spine should be immobilized in the neutral position or in normal axial alignment, as in the anatomic position.^{32,39–42} This position facilitates airway management procedures and application of immobilization devices and reduces spinal cord mor-

bidity that would otherwise result from compromised local circulation. To achieve a neutral position, the spine may need to be manually realigned during the emergency management process.^{32,39} Contraindications for moving the cervical spine to neutral include the following: the movement causes or increases pain, neurologic symptoms, or muscle spasm; the movement would compromise the airway⁴⁰; it is physically difficult to perform the movement; resistance is encountered during the attempt to realign the cervical spine⁴¹; or the patient expresses apprehension.

Although no prospective randomized studies have been conducted to support the above recommendations, evidence can be extrapolated from anatomic and airway management research. Several groups^{48,52–54,128} have investigated the size of the spinal canal in various positions of the cervical spine. Animal-based studies¹²⁹ demonstrate that the extent of spinal cord neurologic injury increases as pressure is sustained and with increasing levels of compression force. Other investigators focused on patients presenting with radicular symptoms⁵⁰ or cervical spondylosis⁵¹ and sought to identify dynamic changes in the spinal canal. Some authors^{49,130} retrospectively investigated the records of patients who sustained cervical spine injuries, assessing how these injuries affected the size of the spinal canal and how that was related to their clinical outcome. Each set of results provides evidence that the optimal position for the spinal cord is the neutral position.

De Lorenzo et al⁴⁸ performed MRI on 19 healthy volunteers to determine the optimal position for cervical spine immobilization. Participants were positioned in neutral and then in 2 cm and 4 cm of cervical flexion and extension. The angle between the cervical and thoracic spines and the ratio between the spinal canal diameter and spinal cord area were identified. Slight flexion (ie, occiput elevated) produced a 3% increase in the ratio of spinal cord area to spinal canal at C5 compared with no elevation, and, therefore, these authors⁴⁸ recommended immobilization in a position of slight flexion. In contrast, Tierney et al⁵⁴ assessed the effect of head position on the cervical space available for the cord in volunteers wearing football equipment. Changes in the sagittal diameter, spinal canal, and spinal cord at the C3–C7 levels were identified on MRI. Increased space was available for the spinal cord at 0 cm of cervical flexion compared with 2 cm and 4 cm of elevation. The space available for the cord was also greatest at the C5–C6 level. The authors⁵⁴ recommended leaving all equipment on and immobilizing the athlete in neutral without any occiput elevation.

Muhle et al⁵² used whole-body MRI to determine the functional changes that occur to the cervical spine and subarachnoid space during dynamic cervical flexion and extension. Nine angles between 50° of flexion and 30° of extension were analyzed. Segmental motion, subarachnoid diameter, and cervical cord diameter were assessed. Decreased ventral subarachnoid space and widened dorsal subarachnoid space were noted during cervical flexion. Correspondingly, during extension, the ventral space increased, while the dorsal space decreased. In addition, the spinal cord diameter decreased 14% during flexion and increased 15% during extension. Depending on the location of the cervical spine injury (ie, dorsal or ventral), the authors⁵² contended that movement of the cervical spine away from neutral may lead to cord compromise.

Ching et al¹²⁸ investigated the effect of postinjury position of the cervical spine on spinal canal occlusion after inducing burst fractures in 8 cadaver cervical spines. Neutral position was defined as *the most central position of the spine that preserved normal lordosis*. The authors then tested the spine in 8 directions (flexion, extension, right and left lateral flexion, and 4 intermediate positions). In addition, right and left cervical rotation, traction, and compression were assessed. Compared with the neutral position, compression, extension, and extension combined with lateral flexion increased canal occlusion.¹²⁸

To identify the relationship between cervical spine sagittal canal diameter and neurologic injury, Eismont et al¹³⁰ retrospectively reviewed the medical records of 98 patients who had sustained closed cervical spine fractures or dislocations. A correlation between mid-sagittal spinal canal size and the onset and degree of neurologic deficit was present. In general, the larger the spinal canal diameter, the less likely the patient was to suffer a neurologic deficit.¹³⁰ More recently, Kang et al⁴⁹ retrospectively analyzed the records and radiographs of 288 patients who had sustained a cervical fracture or dislocation over a 30-year period and also identified an association between the space available for the cord at the level of injury and the severity of neurologic deficit.

In conclusion, for proper functioning of the spinal cord, space within the spinal canal must be maintained, both at rest and during movement. Neurologic injury results from sustained mechanical pressure on the cord, which leads to both anatomic deformation and ischemia.^{129,131} Persistent malposition of an abnormal cervical spine may result in cord compression. If the abnormality is slight, it is likely that the malposition will need to be of greater magnitude and duration to cause harm; as the anatomic derangement increases, the duration of positional stress required to cause harm is shortened.¹²⁹ How much space is available for the cord in any potential cervical spine injury is unknown; therefore, the head and cervical spine must be positioned to create as much potential space for the spinal cord as possible.

Airway

For appropriate management of the spine-injured athlete, the airway should be easily accessible. If the athlete is wearing a face guard that impedes access to the airway, removal of the barrier or insertion of an airway management device is necessary; evidence-based strategies are described in the next section. The airway should be kept open and clear of any obstructions. Potential instability in the cervical spine due to an injury necessitates careful airway management procedures should rescue breathing or introduction of an artificial airway be necessary. In the absence of advanced equipment or training, the airway must be opened using basic techniques that provide cervical spine protection. The jaw-thrust maneuver is recommended over the head-tilt technique, which produces unnecessary motion in the cervical spine. However, the jaw-thrust maneuver may create more motion at the site of injury in the cervical spine than advanced airway maneuvers (ie, esophageal tracheal combitube, laryngoscope endotracheal tube, or laryngeal mask airway).^{55,63,64} If an airway is compromised, airway management is the treatment priority, and the individual with the most

training and experience should apply the safest, most advanced technique available to secure a viable airway and commence rescue breathing.

Patients with potential cervical spine injuries may be treated with the application of a cervical collar or other extrication device. Sports medicine professionals must recognize that it is possible that the application of a semirigid cervical collar may interfere with the ability to open the mouth adequately for certain airway-management techniques,⁵⁶ possibly requiring the loosening or removal of a previously applied external immobilization device, along with any tape or straps that secure the chin.

Transfer and Immobilization

Manual stabilization of the head and neck is initiated early in the care of the potentially spine-injured athlete. Once the primary survey is complete, the next step in most situations is to transfer manual head and neck stabilization to mechanical head and neck immobilization using an external device or devices. Head and cervical spine immobilization devices splint or brace the head and neck as a unit against the upper torso, typically at the intersection of the base of the neck and shoulders. A log roll has historically been used to transfer the patient to a long spine board for full-body immobilization. Other devices and techniques for transfer and full-body immobilization are available and are discussed in the following sections.

Head Stabilization. The capacity of various collars to restrict range of motion in healthy participants and in cadaver models has been assessed,^{70,132–135} with no clear superiority of any single device. One researcher¹³⁶ reported that not only did cervical collars provide no support to the injured cervical spines of cadavers, but in some cases they actually increased motion at the site of injury. Rather, a combination of padding (eg, foam blocks, towels), rigid collar application, and taping to a backboard or full-body splint is recommended⁴⁰; this combination approach has demonstrated the greatest degree of motion limitation at the head during active range of motion in healthy volunteers.^{67,69,70} These findings, combined with reports^{65,66} that manual cervical spine immobilization is superior to the use of external devices in reducing cervical motion during airway intubation, indicate that manual stabilization should be continued throughout the management process, whether or not external stabilization devices are applied.

Transfer and Full-Body Immobilization. Minimizing movement at the head and neck is a critical factor in the successful management of the spine-injured athlete. Any equipment or technique that limits movement will allow for the most effective and safest stabilization of a patient, reducing the potential for secondary injury.⁶⁷ Currently, emergency medical technicians, paramedics, certified athletic trainers, and emergency department personnel typically perform a log roll onto a traditional spine board to stabilize and prepare a patient for transport.^{40,68}

Del Rossi et al^{72–75} compared the log-roll and lift-and-slide techniques by assessing the spine movement created during these tasks in healthy⁷³ individuals and in cadavers with surgically destabilized cervical spines.^{72,74,75} Compared with the lift-and-slide technique, the log-roll

technique produced greater lateral-flexion motion and greater axial rotation of the head in healthy volunteers.⁷³ In another study,⁷² the authors tested cadavers with surgically destabilized cervical spines at the C5–C6 level (a common site of injury in sport-related cervical spine injuries¹³⁷) and found that both techniques created the same amount of movement at the injured cervical spine level. However, only flexion-extension angles were analyzed in that investigation.⁷² The same authors⁷⁵ studied cervical spine movement in multiple planes during the log-roll and lift-and-slide transfer techniques in cadavers with induced destabilizing injuries. The cadavers were also fitted with various cervical collars, but regardless of the collar applied, the log roll created more rotation and lateral flexion than the lift and slide.⁷⁵ In another study⁷⁵ of cadavers with destabilized cervical spines, the log-roll technique resulted in more motion than a “straddle” lift-and-slide technique and the 6-plus-person lift-and-slide technique in multiple planes of motion.

New devices have been developed to challenge the use of the traditional spine board for head and body immobilization. One device is described as a vacuum mattress, which conforms and stiffens around a patient’s body when air is pumped out of the vacuum bag. Several groups have compared the effectiveness of this vacuum mattress to a traditional spine board and found greater comfort⁷¹ and superior immobilization with the vacuum mattress.^{57,69,71}

Despite evidence indicating that lift-and-slide techniques may be more effective in minimizing motion than the log roll or that the use of a vacuum-immobilization device is superior to the traditional spine board, no reports indicate that either the log roll or the traditional spine board has resulted in further compromise of a spine injury. Therefore, the log-roll technique (which is the only method that can be used in prone patients) and the traditional spine board are still considered acceptable for transfer and immobilization of the potentially spine-injured athlete.

The Equipment-Laden Athlete

Equipment and Neutral Cervical Spine Alignment. A number of researchers^{54,76–79,138–141} have investigated whether athletic equipment affects cervical spine alignment. Most have focused on football and how the helmet and shoulder pads may alter the normal lordotic curvature of the cervical spine.^{54,76,77,138,140,141} The equipment worn by ice hockey^{77,78,139} and lacrosse⁷⁹ athletes has also been investigated.

Numerous authors^{76,138,140} have used cadavers to identify the effect of a football helmet and shoulder pads, alone or in combination, on cervical spine alignment. Gastel et al¹³⁸ obtained lateral radiographs on 8 cadaver specimens with both intact and unstable C5–C6 segments. Palumbo et al¹⁴⁰ also used radiography to identify cervical spine alignment in 15 cadavers, 8 of which were destabilized at the C5–C6 level. Both groups reported similar cervical alignment when comparing full equipment (helmet and shoulder pads) with no equipment and an increase in cervical lordosis (approximately 14°) when only the shoulder pads were in place.

Donaldson et al⁷⁶ identified movement in the unstable cervical spines of cadavers during helmet or shoulder-pad removal (or both). Cadaver specimens had cervical spine

instability induced at 1 of 2 levels. Spinal motion was monitored constantly with fluoroscopy while 4 trained individuals removed the equipment. Maximum displacements were identified and compared with the images taken before equipment was removed. Removal of the helmet and shoulder pads correlated with decreased space available for the cord. Helmet removal increased cervical spine flexion, whereas shoulder-pad removal increased extension. Approximately 18° of total movement occurred during equipment removal. Disc height changed 2.3 mm, and the space available for the cord decreased 3.87 mm at the C5–C6 level. The authors⁷⁶ concluded that equipment removal is a very complex and difficult task that can result in potentially dangerous cervical spine motion, especially when the cervical spine is unstable.

Prinsen et al⁷⁷ used fluoroscopy to identify the position of adjacent vertebrae before, during, and after helmet removal and cervical collar application in 11 football players. Vertebral position changed during helmet removal, application of a cervical collar, and while the player lay helmet-less on the spine board.⁷⁷ Swenson et al¹⁴¹ radiographically analyzed cervical spine alignment in 10 male volunteers immobilized on a spine board and found no difference between the no-equipment and full-equipment (shoulder pads plus helmet) conditions. However, with the helmet removed, cervical lordosis increased approximately 10°.¹⁴¹ Using MRI in 12 participants lying on a spine board, Tierney et al⁵⁴ found that the greatest space available for the cord occurred at 0° of elevation with full equipment. The results of these investigations support the recommendation to leave all football equipment on the athlete whenever a cervical spine injury is suspected.

Similar research has been conducted using fluoroscopy,⁷⁷ CT,¹³⁹ or traditional radiographs⁷⁸ in volunteers wearing ice hockey equipment. No differences were noted between the no-equipment and full-equipment conditions. With the helmet removed but shoulder pads on, cervical lordosis was greater than in the control or full-equipment conditions. As in the case of the football player, all equipment should be left on the ice hockey player with a suspected cervical spine injury, provided that the head can be adequately immobilized and that access to the airway is established.

The effect of lacrosse equipment on cervical spine alignment has been investigated by Sherbondy et al,⁷⁹ who compared cervical angles at the levels of the occiput and C2, C2–C7, and the occiput and C-7 in 16 healthy lacrosse players. The cervical angles of the lacrosse players were analyzed in 3 conditions: no equipment, full equipment, and helmet removed. Interestingly, when the lacrosse athletes wore a helmet and shoulder pads (full-equipment condition), lateral CT images revealed an increase in cervical extension (approximately 6°) between the occiput and C7 compared with the no-equipment condition. These changes are different than those previously discussed for football and ice hockey players, in whom the full-equipment conditions left the cervical spine in neutral alignment. With shoulder pads only (helmet removed), cervical flexion increased 4.7° in the occiput to C2 level when compared with full equipment and 4.4° in the C2–C7 level when compared with no equipment.⁷⁹ The increased cervical flexion contrasted with the extension angle noted in football and ice hockey players.

More research is needed regarding the appropriate management of lacrosse equipment, as Sherbondy et al⁷⁹ only looked at a single combination of helmet and shoulder pads, whereas many types of equipment are available in the marketplace. Based on the rationale already discussed regarding the position of the cervical spine for immobilization and transport, if the presence of the supine lacrosse athlete's equipment results in an extended cervical angle, the helmet and shoulder pads may need to be carefully removed to ensure neutral alignment. However, because we do not know how much motion occurs during the removal of the lacrosse helmet and shoulder pads, the rescuer may also elect to transfer the athlete with appropriately fitting equipment in place, provided airway access has been established via face-mask removal.

External Cervical Immobilization Devices. In the equipment-laden athlete, applying a cervical immobilization device may be difficult because of the lack of space between the helmet and shoulder pads and may actually be contraindicated as a result of the motion incurred.⁷⁷ Because the helmet and shoulder pads in some sports (eg, football, ice hockey) provide neutral alignment of the cervical spine, leaving the equipment on without applying a cervical collar before transfer to a spine board is an acceptable practice. One group⁸¹ concluded that a vacuum cervical collar adequately restricted motion in healthy volunteers wearing football equipment. In any sport, if the helmet or shoulder pads must be removed to create neutral alignment, a cervical collar should then be applied immediately.

Helmet, Face-Mask, and Equipment Removal. Although the benefits of wearing protective equipment in terms of reducing the number and severity of impact injuries are obvious, the equipment itself may act as a barrier to effective treatment of an athlete should an injury occur. Knowing how to deal with protective equipment during the immediate care of an athlete with a potential catastrophic cervical spine injury can greatly influence the outcome. Regardless of the sport or the equipment being used, 2 principles should guide management of the equipment-laden athlete with a potential cervical spine injury:

- 1) Exposure and access to vital life functions (airway, chest for cardiopulmonary resuscitation or use of an automated external defibrillator) must be established or easily achieved in a reasonable and acceptable manner.
- 2) Neutral alignment of the cervical spine should be maintained while allowing as little motion as possible at the head and neck.

Football

In the sport of American football, each player is required to wear a helmet (with a face mask) and shoulder pads. These helmets must be designed and constructed in such a way as to meet specific certification standards imposed by NOCSAE.¹⁴² These specifications were devised to protect the wearer from head and facial injuries due to impacts. However, the protective face mask impedes airway access after a potentially catastrophic head or neck injury. Removal of a football helmet created alterations in the position of adjacent cervical vertebrae,^{77,143} although in a

separate study,⁸⁸ no changes were seen in disc height, cervical vertebrae translation, or space available for the cord. Regardless of the conflicting findings, because the helmet and shoulder pads in football players create neutral alignment of the cervical spine, whenever possible, these items should remain in place and the face mask should be removed in order to access the airway.

The technique used for face-mask removal should be the one that creates the least head and neck motion, is performed most quickly, is the least difficult, and carries the least chance of failure. Early recommendations for face-mask removal were to cut all the loop straps rather than unscrew the hardware holding them in place.¹¹⁹ However, a cordless screwdriver is faster^{86,144,145} and easier to use,⁸⁶ and it creates less torque¹⁴⁵ and motion⁸⁶ at the head than do many of the cutting tools commonly used to remove the face mask. Therefore, the cordless screwdriver was recommended for removal of the face mask in place of a cutting tool.^{86,145} However, relying solely on a screwdriver can result in problems that are not encountered with a cutting tool. Screws may not be able to be removed, and problems with the helmet hardware (eg, screws, T-nuts), such as corrosion and rust, can cause the screw face to shred, allowing the T-nut to spin with the screw while turning or even to become so rusted as to fuse the hardware together, preventing any turning at all.^{82,85,146}

These issues, combined with other issues, such as battery life, led to the early opinion¹¹⁹ that a cordless screwdriver for face-mask removal is not reliable and should not be used as a primary tool, but the reliability of the cordless screwdriver has now been assessed. At several sport equipment reconditioning facilities across the country, face masks were removed from a large sample of high school football helmets ($n = 2584$) using a cordless screwdriver. The helmets tested had been used for at least 1 season of play and were at the facilities to be reconditioned. A total of 94% of all screws (9673 of 10284) were successfully removed. All 4 screws were removed from the face mask with the cordless screwdriver in 84% of the entire sample (2165 successful face-mask removals, out of a possible 2584). Among the 419 failed trials, two-thirds of the helmets only had 1 screw removal failure; the remaining one-third had more than 1 screw fail. A success rate of 84% in face-mask removal from such a large sample of helmets provides evidence that the technique is fairly reliable; data for some individual team helmets within the sample showed 100% success, demonstrating that overall reliability could actually be improved. However, because the face mask could not be removed in 16% of the overall sample, concerns are reasonable.

A prospective study⁸² incorporating a combined-tool technique to address the possibility of screw removal failure was performed on a Division II football team. The investigators removed face masks from the helmets of players during the course of a full football season. One researcher used a cordless screwdriver to attempt face-mask removal but was also prepared with a backup cutting tool to cut away loop straps associated with any screw removal failures. At the end of the season, the face mask had been successfully removed from 75 of 76 helmets (a success rate of 98%). Five of 6 loop straps associated with screwdriver failure were removed with the backup cutting tool. One trial was classified as a failure because it exceeded

the 3-minute time limit for all trials. In a separate study,⁸² investigators traveled to sport equipment reconditioning facilities to test this technique on used helmets after the football season was complete. Of 300 face-mask removal attempts with the screwdriver, 57 failed, but those face masks were successfully removed with the backup cutting tool. Thus, 100% of the face masks were removed with the combined-tool approach. The evidence from both studies indicates that this technique is reliable.

From the research to date, we can conclude that the cordless screwdriver is the most efficient tool for face-mask removal in helmets with 4 loop straps and screw and T-nut attachments. Because screw failure is a possibility, the combined-tool technique provides the rescuer the added security of a backup cutting tool. The backup cutting tool could be one specifically designed for this task, such as the Trainers Angel (Riverside, CA), FM Extractor (Sports Medicine Concepts Inc, Livonia, NY), or a tool used for other purposes, such as an anvil pruner. However, this backup cutting tool must be appropriately matched to the helmet and loop strap type being used.⁸⁶

As helmet, face-mask, loop-strap fastener, and tool designs change, so may these specific recommendations. For example, recent changes in the design of the Riddell Revolution football helmet (Riddell Sports Inc, Elyria, OH) include a quick-release attachment system for the face mask. The quick-release system is currently used to attach only the 2 side loop straps, while the top loop straps are secured with the traditional screw and T-nut configuration (Figure 12). Two of the authors (E.E.S. and L.C.D.; unpublished data, 2008) have conducted preliminary research on the quick-release system and found that the average time to remove the face mask was 34.63 ± 14.24 seconds and that the resultant head motion was less than that with a traditional helmet. Regardless of the tool or attachment system, the goal is always to protect the athlete during the management process by minimizing time, motion, and difficulty.

Face-mask removal precludes the need to remove the helmet and shoulder pads in the prehospital setting. However, there may be situations in which exposure of the head, chest, or body is necessary. As stated earlier, anytime either the helmet or shoulder pads should be removed, rescuers should remove both the helmet and shoulder pads. This practice is followed for several reasons, but most importantly, removal of both the helmet and shoulder pads leaves the cervical spine in neutral alignment.¹⁴⁰ Another consideration is that it is much easier to remove the shoulder pads if the helmet has already been removed. Removal of the helmet and shoulder pads using 4 health care providers has been shown⁸⁸ to be effective in limiting motion in the cervical spine of a healthy volunteer, although, as mentioned earlier, other reports^{77,143} have provided conflicting results.

Finally, immediate rescue breathing or cardiopulmonary resuscitation may be necessary for the cervical spine-injured football player. In this situation, a pocket mask may be inserted through the face mask and attached to a bag valve mask, allowing the rescuers to ventilate the patient while the face mask is being removed. Ray et al¹⁴⁷ conducted a study to compare pocket-mask insertion techniques. Inserting the pocket mask through the face-mask eye hole produced less cervical spine movement than



Figure 12. The Riddell Revolution football helmet (Riddell Sports Inc, Elyria, OH) includes a quick-release attachment system for the face mask. The quick-release system is currently used to attach only the 2 side loop straps, while the top loop straps are secured with the traditional screw and T-nut configuration.

inserting it between the chin and the face mask. Both techniques produced less movement than removing the side loop straps by manual screwdriver and rotating the mask. Yet the face-mask eye-hole technique is not feasible for all types of football face masks (eg, those with a center bar or a shield attachment).

Ice Hockey

In ice hockey, research indicates that players lying supine with the helmet and shoulder pads left in place have neutral cervical spine alignment^{78,139} and that removing the helmet may alter that alignment.⁷⁷ As is the case with football and lacrosse helmets, an ice hockey helmet is also reported¹⁴⁸ to immobilize the head of an athlete immobilized on a spine board, provided the helmet was applied correctly and securely. These findings indicate that when an ice hockey player may have a cervical spine injury, the helmet should be left in place.

However, anecdotal reports indicate that not all hockey helmets are worn appropriately. Mihalik et al⁸⁰ investigated head motion created during a prone log roll in hockey players wearing properly fitted helmets, improperly fitted helmets, and no helmets. The smallest amount of head motion occurred when the volunteers wore no helmet at all. With the improperly fitted helmets, the volunteers' heads moved independently, indicating that the rescuers would be unable to secure appropriate head immobilization during the task. The authors⁸⁰ recommended removal of the ice hockey helmet before performing a prone log roll to limit the motion that might otherwise occur. This does present a dilemma, though, in that removal of the ice hockey helmet may cause undue motion in the cervical spine.⁷⁷

If an athlete who is wearing a helmet and shoulder pads has a potential cervical spine injury and the helmet does not provide adequate immobilization or cervical spine alignment or if face-mask removal is not possible, the rescuer may need to remove the helmet. If time and personnel allow, the shoulder pads should also be removed. If time or resources do not allow simultaneous removal of the helmet and shoulder pads, then foam padding or a similar article (eg,

folded towel) should be placed under the head of the athlete to maintain neutral alignment in the cervical spine.

Lacrosse and Other Equipment-Laden Sports

In supine lacrosse players, equipment may not create the same neutral positioning of the cervical spine as that created in football and ice hockey players.⁷⁹ As is the case with football helmets, a lacrosse helmet can provide head immobilization when an athlete is immobilized on a spine board, provided the helmet is applied correctly and fitted securely.¹⁴⁸ These findings indicate that leaving the equipment in place precludes neutral alignment of the cervical spine. Additionally, in many lacrosse helmets, the face masks are not easily removed. Until we can be certain that lacrosse equipment aligns the cervical spine in a neutral position and that the face mask is easily removed, the lacrosse helmet may need to be removed on the field. At this time, however, no researchers have reported on motion created in the cervical spine during lacrosse helmet removal.

Additional data for lacrosse and many other equipment-laden sports and recreational activities, such as horseback riding, downhill skiing, baseball, softball, and mountain biking, are not available. When dealing with a suspected catastrophic cervical spine injury in athletes in these sports, adhering to the 2 underlying principles of managing the equipment-laden athlete dictates the necessary steps during the management process.

Emergency Department Management

The athletic trainer or team physician should accompany the injured athlete to the hospital for several reasons. This practice provides continuity of care, allows for accurate delivery of clinical information to the emergency department staff, and allows the sports medicine professionals to assist emergency department personnel during equipment removal. Unfortunately, this may be difficult or impossible in some settings. Whether or not the sports medicine professional can accompany the athlete, communication between sports medicine and emergency department staffs during the emergency planning phase is important.

Improved communication between team and hospital personnel can only enhance the care delivered. At a minimum, hospital personnel should understand standards of on-field care for the athlete with a potential spine injury and should receive training regarding the proper approach to equipment removal. We recognize that hospital personnel may be unfamiliar with athletic equipment, including helmets, face masks, shoulder pads, and chest protectors. Sports medicine professionals can be a resource for such information, simultaneously increasing communication and improving collegiality.

Equipment Removal and Imaging. Protective equipment should be removed by appropriately trained professionals in the controlled emergency department environment. Previous recommendations⁷⁸ call for clearance plain radiographs to be taken before equipment removal. Although removal of athletic equipment can cause motion in the cervical spine during the process,^{76,77} one group⁸⁸ concluded that it was possible to remove a football helmet and shoulder pads from healthy volunteers without creating significant motion. Two reports^{93,94} documented that obtaining adequate radiographs in healthy, helmeted

football players was difficult. In fact, it is difficult to attain adequate visualization of the full cervical spine even in patients without equipment.^{149–152} Missed diagnoses with negative consequences in nonhelmeted cervical spine-injured patients have been reported; often these consequences included delayed diagnoses related to improper radiographic choices or interpretations.^{152,153} Based on this evidence and the lack of evidence indicating negative consequences caused by equipment removal before radiographic imaging, we cannot make a recommendation to perform radiographic imaging with equipment in place. One group⁹³ suggested that “guidelines for players’ cervical spine imaging should incorporate procedures for removal of equipment before initial radiographic evaluation”; this recommendation offers an alternative to inaccurate diagnoses based on less-than-optimal radiographic findings.

The advent of readily available multidetector CT has replaced the use of plain radiography at many trauma centers, and initial CT evaluation has been recommended^{89–92} in cases involving acute cervical spine trauma. Not only is CT more sensitive, but it carries lower rates of missed primary and secondary injuries,¹⁵⁴ which may spur reconsideration of guidelines for the implementation of CT as the primary diagnostic test for helmeted athletes with suspected cervical spine injuries. Lateral CT scout films have been used with good success in several studies,^{139,141} and CT films with helmet and shoulder pads in place were adequate for initial diagnosis and triage.¹⁵⁵ Although MRI of acute spinal cord injury in the unhelmeted patient provides excellent visualization of neurologic and soft tissue structures, the amount and type of metal within the modern football helmet results in field inhomogeneity and skew artifact (ie, errors in the image), precluding adequate evaluation of the cervical structures and limiting the value of MRI in this setting.⁹⁵

The Roles of Hypothermia Treatment and High-Dose Corticosteroids in the Acute Management of Cervical Spine Injury

The exact mechanism of action is unclear, but hypothermia may slow metabolism, decrease the demand for oxygen, and inhibit a cascade of deleterious chemicals, such as inflammatory agents and excitatory amino acids.^{156,157} Clinical hypothermia has shown promise as a treatment for patients with myocardial infarction, yet potentially deleterious effects (such as sepsis, bleeding, and cardiac arrhythmias) have been demonstrated in patients with brain injury.¹⁵⁷ In addition, rewarming may lead to dangerous drops in blood pressure.¹⁵⁷

Clinical data on hypothermia as a treatment for brain injury and myocardial infarction are abundant, but few clinical reports have addressed hypothermia for spinal cord injury. Laboratory experiments have shown inconsistent effects, and clinical studies^{96,97,156,158–162} have been limited by small sample sizes and a lack of controls. Many unanswered questions concerning hypothermia treatment for spinal cord injury remain, including the following: (1) What is the optimal temperature and duration for hypothermia?¹⁵⁶ (2) How soon after injury must hypothermia be instituted to be effective? (3) Is regional (epidural versus subarachnoid) or systemic cooling more efficacious? (4) What is the best way to rewarm the body after

hypothermia without causing harm? Although regional cooling can lead to faster cooling and fewer systemic effects, technical logistics make this treatment impractical in the management of the on-field athlete. A clinical trial is underway to assess the effects of moderate hypothermia (33°C [92°F]) induced via a cooling catheter placed in the femoral artery immediately after injury. Cooling is maintained for a 48-hour period, followed by slow rewarming of 1°C every 8 hours.¹⁶³ The catheter has a gauge that allows for temperature monitoring. Despite this clinical trial, hypothermia should be considered an experimental treatment that requires further research before being recommended as a standard component of the on-field spinal cord injury management protocol.

In the early 1990s, the use of high-dose methylprednisolone for the treatment of acute spinal cord injury became the standard of care. Bracken et al¹⁶⁴ found that patients with acute spinal cord injury who were treated with high-dose methylprednisolone within the first 8 hours of injury had significant neurologic improvement at the 6-month follow-up compared with a placebo group. The recommended dose of methylprednisolone is an intravenous bolus of 30 mg/kg body weight over 1 hour, followed by infusion at 5.4 mg/kg per hour for 23 hours. One evidence-based review⁹⁸ of the published literature on methylprednisolone revealed serious flaws in data analysis and conclusions, with no clear support for the use of methylprednisolone in patients with acute spinal cord injury. In fact, several studies⁹⁸ showed a higher incidence of respiratory and infectious complications with methylprednisolone. Until additional reliable data are available, the use of high-dose methylprednisolone for acute spinal cord injury remains controversial. When possible, each patient or patient's family should be informed about the risks and benefits of the medication before use.

CONCLUSIONS

In no other sport injury are the elements of efficient immediate care, transport, diagnosis, and treatment more critical to the outcome than in the athlete with a potentially catastrophic cervical spine injury. A high level of evidence (ie, prospective randomized trials) on this topic is in most cases impossible to identify or create. However, the recommendations provided in this position statement are based on the best currently available evidence and expert consensus. Technology, equipment, and techniques will undoubtedly evolve, but the primary goals in managing the spine-injured athlete will remain the same: create as little motion as possible and complete the steps of the emergency action plan as rapidly as is appropriate in order to facilitate transport to the nearest emergency treatment facility.

ACKNOWLEDGMENTS

We gratefully acknowledge the efforts of Robert C. Cantu, MD; Gianluca Del Rossi, PhD, ATC; Roger Härtl, MD; Robert L. Howard, Jr, MA, ATC; Michael Ryan, PT, ATC, PES; Ryan T. Tierney, PhD, ATC; and the Pronouncements Committee in the preparation of this document.

DISCLAIMER

The National Athletic Trainers' Association (NATA) publishes its position statements as a service to promote the awareness of

certain issues to its members. The information contained in the position statement is neither exhaustive nor exclusive to all circumstances or individuals. Variables such as institutional human resource guidelines, state or federal statutes, rules, or regulations, as well as regional environmental conditions may impact the relevance and implementation of these recommendations. The NATA advises its members and others to carefully and independently consider each of the recommendations (including the applicability of same to any particular circumstance or individual). The position statement should not be relied upon as an independent basis for care but rather as a resource available to NATA members or others. Moreover, no opinion is expressed herein regarding the quality of care that adheres to or differs from NATA's position statements. The NATA reserves the right to rescind or modify its position statements at any time.

REFERENCES

1. National Spinal Cord Injury Statistical Center. *Spinal Cord Injury: Facts and Figures at a Glance*. Birmingham: University of Alabama, Birmingham; 2006;2.
2. Nobunaga A, Go BK, Karunas RB. Recent demographic and injury trends in people served by the Model Spine Cord Injury Case Systems. *Arch Phys Med Rehabil*. 1999;80(11):1372-1382.
3. Mueller F, Cantu R. *National Center for Catastrophic Sport Injury Research: Twenty-Fourth Annual Report: Fall 1982-Spring 2006*. Chapel Hill: University of North Carolina; 2008.
4. Mueller FO, Cantu RC. *Annual Survey of Catastrophic Football Injuries, 1977-2006*. Chapel Hill: University of North Carolina; 2006.
5. Boden BP, Tacchetti RL, Cantu RC, Knowles SB, Mueller FO. Catastrophic cervical spine injuries in high school and college football players. *Am J Sports Med*. 2006;34(8):1223-1232.
6. Mueller FO, Cantu RC. *Annual Survey of Catastrophic Football Injuries, 1977-2005*. Chapel Hill: University of North Carolina; 2005.
7. Tator CH, Carson JD, Edmonds VE. Spinal injuries in ice hockey. *Clin Sports Med*. 1998;17(1):183-194.
8. Frymoyer JW, Pope MH, Kristiansen T. Skiing and spinal trauma. *Clin Sports Med*. 1982;1(2):309-318.
9. Hagel BE, Pless B, Platt RW. Trends in emergency department reported head and neck injuries among skiers and snowboarders. *Can J Public Health*. 2003;94(6):458-462.
10. Keene JS. Thoracolumbar fractures in winter sports. *Clin Orthop Relat Res*. 1987;216:39-49.
11. Levy AS, Smith RH. Neurologic injuries in skiers and snowboarders. *Semin Neurol*. 2000;20(2):233-245.
12. Prall JA, Winston KR, Brennan R. Spine and spinal cord injuries in downhill skiers. *J Trauma*. 1995;39(6):1115-1118.
13. Reid DC, Saboe L. Spine fractures in winter sports. *Sports Med*. 1989;7(6):393-399.
14. McCoy GF, Piggot J, Macafee AL, Adair IV. Injuries of the cervical spine in schoolboy rugby football. *J Bone Joint Surg Br*. 1984;66(4):500-503.
15. Scher AT. Catastrophic rugby injuries of the spinal cord: changing patterns of injury. *Br J Sports Med*. 1991;25(1):57-60.
16. Scher AT. Rugby injuries to the cervical spine and spinal cord: a 10-year review. *Clin Sports Med*. 1998;17(1):195-206.
17. Secin FP, Poggi EJ, Luzuriaga F, Laffaye HA. Disabling injuries of the cervical spine in Argentine rugby over the last 20 years. *Br J Sports Med*. 1999;33(1):33-36.
18. Noguchi T. A survey of spinal cord injuries resulting from sport. *Paraplegia*. 1994;32(3):170-173.
19. Silver JR, Silver DD, Godfrey JJ. Injuries of the spine sustained during gymnastic activities. *Br Med J (Clin Res Ed)*. 1986;293(6551):861-863.
20. Torg JS. Epidemiology, pathomechanics, and prevention of athletic injuries to the cervical spine. *Med Sci Sports Exerc*. 1985;17(3):295-303.

21. Bailes JE, Herman JM, Quigley MR, Cerullo LJ, Meyer PR Jr. Diving injuries of the cervical spine. *Surg Neurol.* 1990;34(3):155–158.
22. Boden BP, Pasquina P, Johnson J, Mueller FO. Catastrophic injuries in pole-vaulters. *Am J Sports Med.* 2001;29(1):50–54.
23. Boden BP, Tacchetti R, Mueller FO. Catastrophic cheerleading injuries. *Am J Sports Med.* 2003;31(6):881–888.
24. Boden BP, Tacchetti R, Mueller FO. Catastrophic injuries in high school and college baseball players. *Am J Sports Med.* 2004;32(5):1189–1196.
25. Toscano J. Prevention of neurological deterioration before admission to a spinal cord injury unit. *Paraplegia.* 1988;26(3):143–150.
26. Masini M, Alencar MR, Neves EG, Alves CF. Spinal cord injury: patients who had an accident, walked but became spinal paralysed. *Paraplegia.* 1994;32(2):93–97.
27. Cusick JF, Yoganandan N. Biomechanics of the cervical spine 4: major injuries. *Clin Biomech (Bristol, Avon).* 2002;17(1):1–20.
28. Banerjee R, Palumbo MA, Fadale PD. Catastrophic cervical spine injuries in the collision sport athlete, part 1: epidemiology, functional anatomy, and diagnosis. *Am J Sports Med.* 2004;32(4):1077–1087.
29. Mueller FO, Cantu RC. *National Center for Catastrophic Sport Injury Research: Twenty-Second Annual Report, Fall 1982–Spring 2004.* Chapel Hill: University of North Carolina; 2005.
30. Heck JF, Clarke KS, Peterson TR, Torg JS, Weis MP. National Athletic Trainers' Association position statement: head-down contact and spearing in tackle football. *J Athl Train.* 2004;39(1):101–111.
31. Andersen J, Courson RW, Kleiner DM, McLoda TA. National Athletic Trainers' Association position statement: emergency planning in athletics. *J Athl Train.* 2002;37(1):99–104.
32. Crosby E. Airway management after upper cervical spine injury: what have we learned? *Can J Anaesth.* 2002;49(7):733–744.
33. Sanchez AR II, Sugalski MT, LaPrade RF. Field-side and prehospital management of the spine-injured athlete. *Curr Sports Med Rep.* 2005;4(1):50–55.
34. Domeier RM, Frederiksen SM, Welch K. Prospective performance assessment of an out-of-hospital protocol for selective spine immobilization using clinical spine clearance criteria. *Ann Emerg Med.* 2005;46(2):123–131.
35. Domeier RM, Swor RA, Evans RW, et al. Multicenter prospective validation of prehospital clinical spinal clearance criteria. *J Trauma.* 2002;53(4):744–750.
36. Holly LT, Kelly DF, Counelis GJ, Blinman T, McArthur DL, Cryer HG. Cervical spine trauma associated with moderate and severe head injury: incidence, risk factors, and injury characteristics. *J Neurosurg.* 2002;96(suppl 3):285–291.
37. Iida H, Tachibana S, Kitahara T, Horiike S, Ohwada T, Fujii K. Association of head trauma with cervical spine injury, spinal cord injury, or both. *J Trauma.* 1999;46(3):450–452.
38. Cantu RC. The cervical spinal stenosis controversy. *Clin Sports Med.* 1998;17(1):121–126.
39. Crosby ET. Airway management in adults after cervical spine trauma. *Anesthesiology.* 2006;104(6):1293–1318.
40. De Lorenzo RA. A review of spinal immobilization techniques. *J Emerg Med.* 1996;14(5):603–613.
41. Gabbott DA, Baskett PJ. Management of the airway and ventilation during resuscitation. *Br J Anaesth.* 1997;79(2):159–171.
42. Lennarson PJ, Smith D, Todd MM, et al. Segmental cervical spine motion during orotracheal intubation of the intact and injured spine with and without external stabilization. *J Neurosurg.* 2000;92(suppl 2):201–206.
43. Bivins HG, Ford S, Bezmalinovic Z, Price HM, Williams JL. The effect of axial traction during orotracheal intubation of the trauma victim with an unstable cervical spine. *Ann Emerg Med.* 1988;17(1):25–29.
44. Ghafoor AU, Martin TW, Gopalakrishnan S, Viswamitra S. Caring for the patients with cervical spine injuries: what have we learned? *J Clin Anesth.* 2005;17(8):640–649.
45. Kaufman HH, Harris JH Jr, Spencer JA, Kopanisky DR. Danger of traction during radiography for cervical trauma. *JAMA.* 1982;247(17):2369.
46. Lennarson PJ, Smith DW, Sawin PD, Todd MM, Sato Y, Traynelis VC. Cervical spinal motion during intubation: efficacy of stabilization maneuvers in the setting of complete segmental instability. *J Neurosurg.* 2001;94(suppl 2):265–270.
47. Chang DG, Tencer AF, Ching RP, Treece B, Senft D, Anderson PA. Geometric changes in the cervical spinal canal during impact. *Spine.* 1994;19(8):973–980.
48. De Lorenzo RA, Olson JE, Boska M, et al. Optimal positioning for cervical immobilization. *Ann Emerg Med.* 1996;28(3):301–308.
49. Kang JD, Figgie MP, Bohlman HH. Sagittal measurements of the cervical spine in subaxial fractures and dislocations: an analysis of two hundred and eighty-eight patients with and without neurological deficits. *J Bone Joint Surg Am.* 1994;76(11):1617–1628.
50. Muhle C, Bischoff L, Weinert D, et al. Exacerbated pain in cervical radiculopathy at axial rotation, flexion, extension, and coupled motions of the cervical spine: evaluation by kinematic magnetic resonance imaging. *Invest Radiol.* 1998;33(5):279–288.
51. Muhle C, Weinert D, Falliner A, et al. Dynamic changes of the spinal canal in patients with cervical spondylosis at flexion and extension using magnetic resonance imaging. *Invest Radiol.* 1998;33(8):444–449.
52. Muhle C, Wiskirchen J, Weinert D, et al. Biomechanical aspects of the subarachnoid space and cervical cord in healthy individuals examined with kinematic magnetic resonance imaging. *Spine.* 1998;23(5):556–567.
53. Tierney RT, Maldjian C, Mattacola CG, Straub SJ, Sitler MR. Cervical spine stenosis measures in normal subjects. *J Athl Train.* 2002;37(2):190–193.
54. Tierney RT, Mattacola CG, Sitler MR, Maldjian C. Head position and football equipment influence cervical spinal-cord space during immobilization. *J Athl Train.* 2002;37(2):185–189.
55. Aprahamian C, Thompson BM, Finger WA, Darin JC. Experimental cervical spine injury model: evaluation of airway management and splinting techniques. *Ann Emerg Med.* 1984;13(8):584–587.
56. Goutcher CM, Lochhead V. Reduction in mouth opening with semi-rigid cervical collars. *Br J Anaesth.* 2005;95(3):344–348.
57. Johnson DR, Hauswald M, Stockhoff C. Comparison of a vacuum splint device to a rigid backboard for spinal immobilization. *Am J Emerg Med.* 1996;14(4):369–372.
58. Banerjee R, Palumbo MA, Fadale PD. Catastrophic cervical spine injuries in the collision sport athlete, part 2: principles of emergency care. *Am J Sports Med.* 2004;32(7):1760–1764.
59. Holley J, Jorden R. Airway management in patients with unstable cervical spine fractures. *Ann Emerg Med.* 1989;18(11):1237–1239.
60. Lord SA, Boswell WC, Williams JS, Odom JW, Boyd CR. Airway control in trauma patients with cervical spine fractures. *Prehosp Disaster Med.* 1994;9(1):44–49.
61. Brimacombe J, Keller C, Kunzel KH, Gaber O, Boehler M, Puhlinger F. Cervical spine motion during airway management: a cinefluoroscopic study of the posteriorly destabilized third cervical vertebrae in human cadavers. *Anesth Analg.* 2000;91(5):1274–1278.
62. Criswell JC, Parr MJ, Nolan JP. Emergency airway management in patients with cervical spine injuries. *Anaesthesia.* 1994;49(10):900–903.
63. Hauswald M, Sklar DP, Tandberg D, Garcia JF. Cervical spine movement during airway management: cinefluoroscopic appraisal in human cadavers. *Am J Emerg Med.* 1991;9(6):535–538.
64. Donaldson WF III, Heil BV, Donaldson VP, Silvaggio VJ. The effect of airway maneuvers on the unstable C1–C2 segment: a cadaver study. *Spine.* 1997;22(11):1215–1218.
65. Gerling MC, Davis DP, Hamilton RS, et al. Effects of cervical spine immobilization technique and laryngoscope blade selection on an unstable cervical spine in a cadaver model of intubation. *Ann Emerg Med.* 2000;36(4):293–300.
66. Majernick TG, Bieniek R, Houston JB, Hughes HG. Cervical spine movement during orotracheal intubation. *Ann Emerg Med.* 1986;15(4):417–420.

67. Chandler DR, Nemejc C, Adkins RH, Waters RL. Emergency cervical-spine immobilization. *Ann Emerg Med.* 1992;21(10):1185–1188.
68. Dasen KR. On-field management for the injured football player. *Clin J Sport Med.* 2000;10(1):82–83.
69. Hamilton RS, Pons PT. The efficacy and comfort of full-body vacuum splints for cervical-spine immobilization. *J Emerg Med.* 1996;14(5):553–559.
70. Podolsky S, Baraff LJ, Simon RR, Hoffman JR, Larmon B, Ablon W. Efficacy of cervical spine immobilization methods. *J Trauma.* 1983;23(6):461–465.
71. Luscombe MD, Williams JL. Comparison of a long spinal board and vacuum mattress for spinal immobilisation. *Emerg Med J.* 2003;20(5):476–478.
72. Del Rossi G, Horodyski M, Heffernan TP, et al. Spine-board transfer techniques and the unstable cervical spine. *Spine.* 2004;29(7):E134–E138.
73. Del Rossi G, Horodyski M, Powers ME. A comparison of spine-board transfer techniques and the effect of training on performance. *J Athl Train.* 2003;38(3):204–208.
74. Del Rossi G, Horodyski MH, Conrad BP, Di Paola CP, Di Paola MJ, Rehtine GR. The 6-plus-person lift transfer technique compared with other methods of spine boarding. *J Athl Train.* 2008;43(1):6–13.
75. Del Rossi G, Heffernan TP, Horodyski M, Rehtine GR. The effectiveness of extrication collars tested during the execution of spine-board transfer techniques. *Spine J.* 2004;4(6):619–623.
76. Donaldson WF III, Laueran WC, Heil B, Blanc R, Swenson T. Helmet and shoulder pad removal from a player with suspected cervical spine injury: a cadaveric model. *Spine.* 1998;23(16):1729–1733.
77. Prinsen RK, Syrotoik DG, Reid DC. Position of the cervical vertebrae during helmet removal and cervical collar application in football and hockey. *Clin J Sport Med.* 1995;5(3):155–161.
78. Metz CM, Kuhn JE, Greenfield ML. Cervical spine alignment in immobilized hockey players: radiographic analysis with and without helmets and shoulder pads. *Clin J Sport Med.* 1998;8(2):92–95.
79. Sherbondy PS, Hertel JN, Sebastianelli WJ. The effect of protective equipment on cervical spine alignment in collegiate lacrosse players. *Am J Sports Med.* 2006;34(10):1675–1679.
80. Mihalik JP, Beard JR, Petschauer MA, Prentice WE, Guskiewicz KM. Effect of ice hockey helmet fit on cervical spine motion during an emergency log roll procedure. *Clin J Sport Med.* 2008;18(5):394–398.
81. Ransone J, Kersey R, Walsh K. The efficacy of the Rapid Form Cervical Vacuum Immobilizer in cervical spine immobilization of the equipped football player. *J Athl Train.* 2000;35(1):65–69.
82. Copeland AJ, Decoster LC, Swartz EE, Gattie ER, Gale SD. Combined tool approach is 100% successful for emergency football face mask removal. *Clin J Sport Med.* 2007;17(6):452–457.
83. Gale SD, Decoster LC, Swartz EE. The combined tool approach for face mask removal during on-field conditions. *J Athl Train.* 2008;43(1):14–20.
84. Swartz EE, Armstrong CW, Rankin JM, Rogers B. A 3-dimensional analysis of face-mask removal tools in inducing helmet movement. *J Athl Train.* 2002;37(2):178–184.
85. Swartz EE, Decoster LC, Norkus SA, Cappaert TA. The influence of various factors on high school football helmet face mask removal: a retrospective, cross-sectional analysis. *J Athl Train.* 2007;42(1):11–20.
86. Swartz EE, Norkus SA, Cappaert T, Decoster L. Football equipment design affects face mask removal efficiency. *Am J Sports Med.* 2005;33(8):1210–1219.
87. Swartz EE, Norkus SA, Armstrong CW, Kleiner DM. Face-mask removal: movement and time associated with cutting of the loop straps. *J Athl Train.* 2003;38(2):120–125.
88. Peris MD, Donaldson WF III, Towers J, Blanc R, Muzzonigro TS. Helmet and shoulder pad removal in suspected cervical spine injury: human control model. *Spine.* 2002;27(9):995–999.
89. Hanson JA, Blackmore CC, Mann FA, Wilson AJ. Cervical spine injury: a clinical decision rule to identify high-risk patients for helical CT screening. *Am J Roentgenol.* 2000;174(3):713–717.
90. Li AE, Fishman EK. Cervical spine trauma: evaluation by multi-detector CT and three-dimensional volume rendering. *Emerg Radiol.* 2003;10(1):34–39.
91. Schleeauf K, Ross SE, Civil ID, Schwab CW. Computed tomography in the initial evaluation of the cervical spine. *Ann Emerg Med.* 1989;18(8):815–817.
92. Quencer RM, Nunez D, Green BA. Controversies in imaging acute cervical spine trauma. *Am J Neuroradiol.* 1997;18(10):1866–1868.
93. Davidson RM, Burton JH, Snowise M, Owens WB. Football protective gear and cervical spine imaging. *Ann Emerg Med.* 2001;38(1):26–30.
94. Veenema K, Greenwald R, Kamali M, Freedman A, Spillane L. The initial lateral cervical spine film for the athlete with a suspected neck injury: helmet and shoulder pads on or off? *Clin J Sport Med.* 2002;12(2):123–126.
95. Waninger KN, Rothman M, Heller M. MRI is nondiagnostic in cervical spine imaging of the helmeted football player with shoulder pads. *Clin J Sport Med.* 2003;13(6):353–357.
96. Guest JD, Vanni S, Silbert L. Mild hypothermia, blood loss and complications in elective spinal surgery. *Spine J.* 2004;4(2):130–137.
97. Martinez-Arizala A, Green BA. Hypothermia in spinal cord injury. *J Neurotrauma.* 1992;9(suppl 2):S497–S505.
98. Hurlbert RJ. The role of steroids in acute spinal cord injury: an evidence-based analysis. *Spine.* 2001;26(suppl 24):S39–S46.
99. Boden BP. Direct catastrophic injury in sports. *J Am Acad Orthop Surg.* 2005;13(7):445–454.
100. Nightingale RW, McElhaney JH, Richardson WJ, Best TM, Myers BS. Experimental impact injury to the cervical spine: relating motion of the head and the mechanism of injury. *J Bone Joint Surg Am.* 1996;78(3):412–421.
101. Nightingale RW, McElhaney JH, Richardson WJ, Myers BS. Dynamic responses of the head and cervical spine to axial impact loading. *J Biomech.* 1996;29(3):307–318.
102. Nightingale RW, Camacho DL, Armstrong AJ, Robinette JJ, Myers BS. Inertial properties and loading rates affect buckling modes and injury mechanisms in the cervical spine. *J Biomech.* 2000;33(2):191–197.
103. Penning L. Kinematics of cervical spine injury: a functional radiological hypothesis. *Eur Spine J.* 1995;4(2):126–132.
104. Amevo B, Aprill C, Bogduk N. Abnormal instantaneous axes of rotation in patients with neck pain. *Spine.* 1992;17(7):748–756.
105. Yoganandan N, Pintar F, Butler J, Reinartz J, Sances A Jr, Larson SJ. Dynamic response of human cervical spine ligaments. *Spine.* 1989;14(10):1102–1110.
106. Nightingale RW, Richardson WJ, Myers BS. The effects of padded surfaces on the risk for cervical spine injury. *Spine.* 1997;22(20):2380–2387.
107. Penning L. Some aspects of plain radiography of the cervical spine in chronic myelopathy. *Neurology.* 1962;12:513–519.
108. Torg JS. Cervical spinal stenosis with cord neuropathia and transient quadriplegia. *Sports Med.* 1995;20(6):429–434.
109. Osterholm J. The catecholamine hypothesis of spinal cord injury. In: Wilkins R, ed. *The Pathophysiology of Spinal Cord Trauma*. Springfield, IL: Thomas; 1978:41–45.
110. Osterholm J. The histopathology of the wounded spinal cord. In: Wilkins R, ed. *The Pathophysiology of Spinal Cord Trauma*. Springfield, IL: Thomas; 1978:17–28.
111. Osterholm J, Alderman J, Irvin J. The biochemistry of spinal cord injury. In: Wilkins R, ed. *The Pathophysiology of Spinal Cord Trauma*. Springfield, IL: Thomas; 1978:66–87.
112. National Operating Committee for Standards on Athletic Equipment. About NOCSAE: history and purpose. <http://www.nocsae.org/about/history.html>. Accessed April 12, 2008.
113. National Collegiate Athletic Association. *Football Rules and Interpretations*. Indianapolis, IN: National Collegiate Athletic Association; 2008:32.

114. National Operating Committee for Standards on Athletic Equipment. *Standard Performance Specification for Recertified Football Helmets*. Overland Park, KS: National Operating Committee on Standards for Athletic Equipment; 2004:1–2.
115. Torg JS, Vegso JJ, O'Neill MJ, Sennett B. The epidemiologic, pathologic, biomechanical, and cinematographic analysis of football-induced cervical spine trauma. *Am J Sports Med*. 1990;18(1):50–57.
116. Boden BP, Prior C. Catastrophic spine injuries in sports. *Curr Sports Med Rep*. 2005;4(1):45–49.
117. Tator CH, Provvidenza CF, Lapczak L, Carson J, Raymond D. Spinal injuries in Canadian ice hockey: documentation of injuries sustained from 1943–1999. *Can J Neurol Sci*. 2004;31(4):460–466.
118. Torg JS, Vegso JJ, Sennett B, Das M. The National Football Head and Neck Injury Registry: 14-year report on cervical quadriplegia, 1971 through 1984. *JAMA*. 1985;254(24):3439–3443.
119. Kleiner DM, Almquist JL, Bailes J, et al. *Prehospital Care of the Spine-Injured Athlete: A Document From the Inter-Association Task Force for Appropriate Care of the Spine-Injured Athlete*. Dallas, TX: National Athletic Trainers' Association; 2001.
120. Balady GJ, Chaitman B, Foster C, Froelicher E, Gordon N, Van Camp S. Automated external defibrillators in health/fitness facilities: supplement to the AHA/ACSM Recommendations for Cardiovascular Screening, Staffing, and Emergency Policies at Health/Fitness Facilities. *Circulation*. 2002;105(9):1147–1150.
121. Swartz EE, Nowak J, Shirley C, Decoster LC. A comparison of head movement during back boarding by motorized spine-board and log-roll techniques. *J Athl Train*. 2005;40(3):162–168.
122. Weller J, Robinson B, Larsen P, Caldwell C. Simulation-based training to improve acute care skills in medical undergraduates. *N Z Med J*. 2004;117(1204):U1119.
123. Martin M, Scalabrini B, Rioux A, Xhignesse MA. Training fourth-year medical students in critical invasive skills improves subsequent patient safety. *Am Surg*. 2003;69(5):437–440.
124. Cooper DJ, Ackland HM. Clearing the cervical spine in unconscious head injured patients: the evidence. *Crit Care Resusc*. 2005;7(3):181–184.
125. Hankins DG, Rivera-Rivera EJ, Ornato JP, Swor RA, Blackwell T, Domeier RM, Turtle Creek Conference II. Spinal immobilization in the field: clinical clearance criteria and implementation. *Prehosp Emerg Care*. 2001;5(1):88–93.
126. Demetriades D, Charalambides K, Chahwan S, et al. Nonskeletal cervical spine injuries: epidemiology and diagnostic pitfalls. *J Trauma*. 2000;48(4):724–727.
127. Ross SE, O'Malley KF, DeLong WG, Born CT, Schwab CW. Clinical predictors of unstable cervical spinal injury in multiply injured patients. *Injury*. 1992;23(5):317–319.
128. Ching RP, Watson NA, Carter JW, Tencer AF. The effect of post-injury spinal position on canal occlusion in a cervical spine burst fracture model. *Spine*. 1997;22(15):1710–1715.
129. Carlson GD, Gorden CD, Oliff HS, Pillai JJ, LaManna JC. Sustained spinal cord compression, part I: time-dependent effect on long-term pathophysiology. *J Bone Joint Surg Am*. 2003;85(1):86–94.
130. Eismont FJ, Clifford S, Goldberg M, Green B. Cervical sagittal spinal canal size in spine injury. *Spine*. 1984;9(7):663–666.
131. Delamarter RB, Sherman J, Carr JB. Pathophysiology of spinal cord injury: recovery after immediate and delayed decompression. *J Bone Joint Surg Am*. 1995;77(7):1042–1049.
132. Askins V, Eismont FJ. Efficacy of five cervical orthoses in restricting cervical motion: a comparison study. *Spine*. 1997;22(11):1193–1198.
133. James CY, Riemann BL, Munkasy BA, Joyner AB. Comparison of cervical spine motion during application among 4 rigid immobilization collars. *J Athl Train*. 2004;39(2):138–145.
134. McCabe JB, Nolan DJ. Comparison of the effectiveness of different cervical immobilization collars. *Ann Emerg Med*. 1986;15(1):50–53.
135. Rosen PB, McSwain NE Jr, Arata M, Stahl S, Mercer D. Comparison of two new immobilization collars. *Ann Emerg Med*. 1992;21(10):1189–1195.
136. Bednar DA. Efficacy of orthotic immobilization of the unstable subaxial cervical spine of the elderly patient: investigation in a cadaver model. *Can J Surg*. 2004;47(4):251–256.
137. Torg JS, Guille JT, Jaffe S. Injuries to the cervical spine in American football players. *J Bone Joint Surg Am*. 2002;84(1):112–122.
138. Gastel JA, Palumbo MA, Hulstyn MJ, Fadale PD, Lucas P. Emergency removal of football equipment: a cadaveric cervical spine injury model. *Ann Emerg Med*. 1998;32(4):411–417.
139. Laprade RF, Schnetzler KA, Broxterman RJ, Wentorf F, Gilbert TJ. Cervical spine alignment in the immobilized ice hockey player: a computed tomographic analysis of the effects of helmet removal. *Am J Sports Med*. 2000;28(6):800–803.
140. Palumbo MA, Hulstyn MJ, Fadale PD, O'Brien T, Shall L. The effect of protective football equipment on alignment of the injured cervical spine: radiographic analysis in a cadaveric model. *Am J Sports Med*. 1996;24(4):446–453.
141. Swenson TM, Laueran WC, Blanc RO, Donaldson WF III, Fu FH. Cervical spine alignment in the immobilized football player: radiographic analysis before and after helmet removal. *Am J Sports Med*. 1997;25(2):226–230.
142. National Operating Committee on Standards for Athletic Equipment. *Standard Performance Specification for Newly Manufactured Football Helmets*. Overland Park, KS: National Operating Committee on Standards for Athletic Equipment; 2003:1–5.
143. Aprahamian C, Thompson BM, Darin JC. Recommended helmet removal techniques in a cervical spine injured patient. *J Trauma*. 1984;24(9):841–842.
144. Ray R, Luchies C, Bazuin D, Farrell RN. Airway preparation techniques for the cervical spine-injured football player. *J Athl Train*. 1995;30(3):217–221.
145. Jenkins HL, Valovich TC, Arnold BL, Gansneder BM. Removal tools are faster and produce less force and torque on the helmet than cutting tools during face-mask retraction. *J Athl Train*. 2002;37(3):246–251.
146. Decoster LC, Shirley CP, Swartz EE. Football face-mask removal with a cordless screwdriver on helmets used for at least one season of play. *J Athl Train*. 2005;40(3):169–173.
147. Ray R, Luchies C, Frens MA, Hughes W, Sturmfels R. Cervical spine motion in football players during 3 airway-exposure techniques. *J Athl Train*. 2002;37(2):172–177.
148. Waninger KN, Richards JG, Pan WT, Shay AR, Shindle MK. An evaluation of head movement in backboard-immobilized helmeted football, lacrosse, and ice hockey players. *Clin J Sport Med*. 2001;11(2):82–86.
149. Woodring JH, Lee C. Limitations of cervical radiography in the evaluation of acute cervical trauma. *J Trauma*. 1993;34(1):32–39.
150. Spain DA, Trooskin SZ, Flancaum L, Boyarsky AH, Noshier JL. The adequacy and cost effectiveness of routine resuscitation-area cervical-spine radiographs. *Ann Emerg Med*. 1990;19(3):276–278.
151. Gerrelts BD, Petersen EU, Mabry J, Petersen SR. Delayed diagnosis of cervical spine injuries. *J Trauma*. 1991;31(12):1622–1626.
152. Davis JW, Phreaner DL, Hoyt DB, Mackersie RC. The etiology of missed cervical spine injuries. *J Trauma*. 1993;34(3):342–346.
153. Poonnoose PM, Ravichandran G, McClelland MR. Missed and mismanaged injuries of the spinal cord. *J Trauma*. 2002;53(2):314–320.
154. Griffen MM, Frykberg ER, Kerwin AJ, et al. Radiographic clearance of blunt cervical spine injury: plain radiograph or computed tomography scan? *J Trauma*. 2003;55(2):222–227.
155. Waninger KN, Rothman M, Foley J, Heller M. Computed tomography is diagnostic in the cervical imaging of helmeted football players with shoulder pads. *J Athl Train*. 2004;39(3):217–222.
156. Guest JD, Dietrich WD. Spinal cord ischemia and trauma. In: Tisherman SA, & Sterz F, eds. *Therapeutic Hypothermia*. Dordrecht, The Netherlands: Kluwer Academic Publishers; 2005:101–118.
157. Couzin J. Medicine: the big chill. *Science*. 2007;317(5839):743–745.
158. Yu CG, Jimenez O, Marcillo AE, et al. Beneficial effects of modest systemic hypothermia on locomotor function and histopathological damage following contusion-induced spinal cord injury in rats. *J Neurosurg*. 2000;93(suppl 1):85–93.

159. Chatzipanteli K, Yanagawa Y, Marcillo AE, Kraydieh S, Yezierski RP, Dietrich WD. Posttraumatic hypothermia reduces polymorphonuclear leukocyte accumulation following spinal cord injury in rats. *J Neurotrauma*. 2000;17(4):321–332.
160. Green BA, Khan T, Raimondi AJ. Local hypothermia as treatment of experimentally induced spinal cord contusion: quantitative analysis of beneficial effect. *Surg Forum*. 1973;24:436–438.
161. Busto R, Dietrich WD, Globus MY, Ginsberg MD. Postischemic moderate hypothermia inhibits CA1 hippocampal ischemic neuronal injury. *Neurosci Lett*. 1989;101(3):299–304.
162. Green EJ, Pazos AJ, Dietrich WD, et al. Combined postischemic hypothermia and delayed MK-801 treatment attenuates neurobehavioral deficits associated with transient global ischemia in rats. *Brain Res*. 1995;702(1–2):145–152.
163. The Miami Project to Cure Paralysis. Clinical trials initiative: therapeutic hypothermia for acute spinal cord injury and traumatic brain injury. <http://216.235.203.137/Page.aspx?pid=339>. Accessed May 10, 2008.
164. Bracken MB, Shepard MJ, Collins WF, et al. A randomized, controlled trial of methylprednisolone or naloxone in the treatment of acute spinal-cord injury: results of the Second National Acute Spinal Cord Injury Study. *N Engl J Med*. 1990;322(20):1405–1411.
165. Kwan I, Bunn F. Effects of prehospital spinal immobilization: a systematic review of randomized trials on healthy subjects. *Prehosp Disaster Med*. 2005;20(1):47–53.
166. Mazolewski P, Manix TH. The effectiveness of strapping techniques in spinal immobilization. *Ann Emerg Med*. 1994;23(6):1290–1295.

Appendix A. Clinical Considerations in the Management Protocol for the Spine-Injured Athlete: Transfer and Immobilization

FULL-BODY IMMOBILIZATION

To achieve full spinal immobilization during on-the-field management of an injury, patients are typically transferred and then secured to a long spine board. The task of moving a patient to a spine board can prove challenging, as the head and trunk must be moved as a unit. Spine boarding athletes may present additional challenges, from the size of the athlete to equipment considerations to athletic venue barriers or obstacles, such as spine boarding an athlete from a swimming pool, a pole-vault pit, or a gymnastics foam pit.

A variety of techniques exist to move and immobilize the injured athlete. Rescuers should use the technique that they have reviewed and rehearsed and are most comfortable with and, most importantly, that produces the least amount of spinal movement.

SELECTION OF APPROPRIATE TRANSFER AND SPINE-BOARDING TECHNIQUES

Supine Log-Roll Technique

When transferring an athlete found in the supine position to a spine board, the supine log-roll technique may be used. The rescuer in charge (rescuer 1) provides cervical spine stabilization. Ideally, 3 additional rescuers are positioned on 1 side of the athlete, with rescuer 2 at the shoulders and thorax, rescuer 3 at the hips, and rescuer 4 at the legs. Rescuer 5 is positioned on the opposite side of the athlete with the spine board. Rescuers 2 through 4 reach across the athlete and, on command from rescuer 1, carefully roll the athlete toward them while rescuer 5

positions the spine board at a 45° angle beneath the athlete. On command, rescuers 2 through 4 slowly lower the athlete as rescuer 5 controls the spine board. Throughout this process, rescuer 1 provides all commands while maintaining manual cervical spine immobilization. The supine log-roll technique may also be used for the athlete found in the side-lying position.

Prone Log-Roll Technique

When transferring an athlete found in the prone position to a spine board, the prone log-roll technique may be used. Two variations to this technique are the prone log-roll pull and prone log-roll push. In the prone log-roll pull, the rescuer in charge (rescuer 1) provides cervical spine stabilization, crossing his or her hands initially, so that when the roll is complete, the hands are uncrossed. Ideally, 3 additional rescuers are positioned on 1 side of the athlete, with rescuer 2 at the shoulders and thorax, rescuer 3 at the hips, and rescuer 4 at the legs. Rescuer 1 directs the other rescuers to position themselves on the appropriate side of the athlete. In some instances, the athlete may be prone with the head turned to 1 side. In this case, rescuer 1 directs rescuers 2 through 4 to position themselves on the side opposite the athlete's face. Rescuer 5 is positioned on the same side as the other rescuers, holding the spine board at the feet of the athlete. Rescuers 2 through 4 reach across the athlete and, on command from rescuer 1, carefully roll the athlete by pulling toward them. When the athlete is pulled onto his or her side, rescuers 1 through 4 pause while rescuer 5 carefully slides the spine board between rescuers 2 through 4 and the athlete. On command, rescuers 2 through 4 slowly lower the athlete as rescuer 5 controls the spine board. Throughout this process, rescuer 1 provides all commands while maintaining manual cervical spine immobilization.

It may be difficult for rescuer 5 to slide the spine board between the athlete and rescuers 2 through 4 without touching each other's arms and possibly jeopardizing their hold on the athlete. To address this issue, an alternative technique is the prone log-roll push, shown in Figure 1.

Lift-and-Slide Technique

An alternative to the log roll is the lift-and-slide transfer technique. Variations include the 6-plus-person lift and the straddle lift and slide. In contrast to the log roll, in which the athlete is rolled to a side-lying position and the spine board is positioned beneath him or her, with the lift-and-slide technique the athlete is simply lifted off the ground to allow for spine board placement. The premise behind the lift-and-slide technique is that the work of lifting the athlete is handled efficiently by involving 4 to 7 rescuers. In addition, this technique avoids rolling the injured athlete over the arm, as well as over possibly bulky protective equipment, and, therefore, this technique may be extremely effective at minimizing structural interference that could result in unwanted spinal column movements.^{72,73} The lift-and-slide technique may only be used for supine athletes, whereas a prone athlete must be log rolled for transfer to a spine board.

The 6-plus-person lift is shown in Figure 2. A disadvantage of this procedure is that it requires 6 additional rescuers.

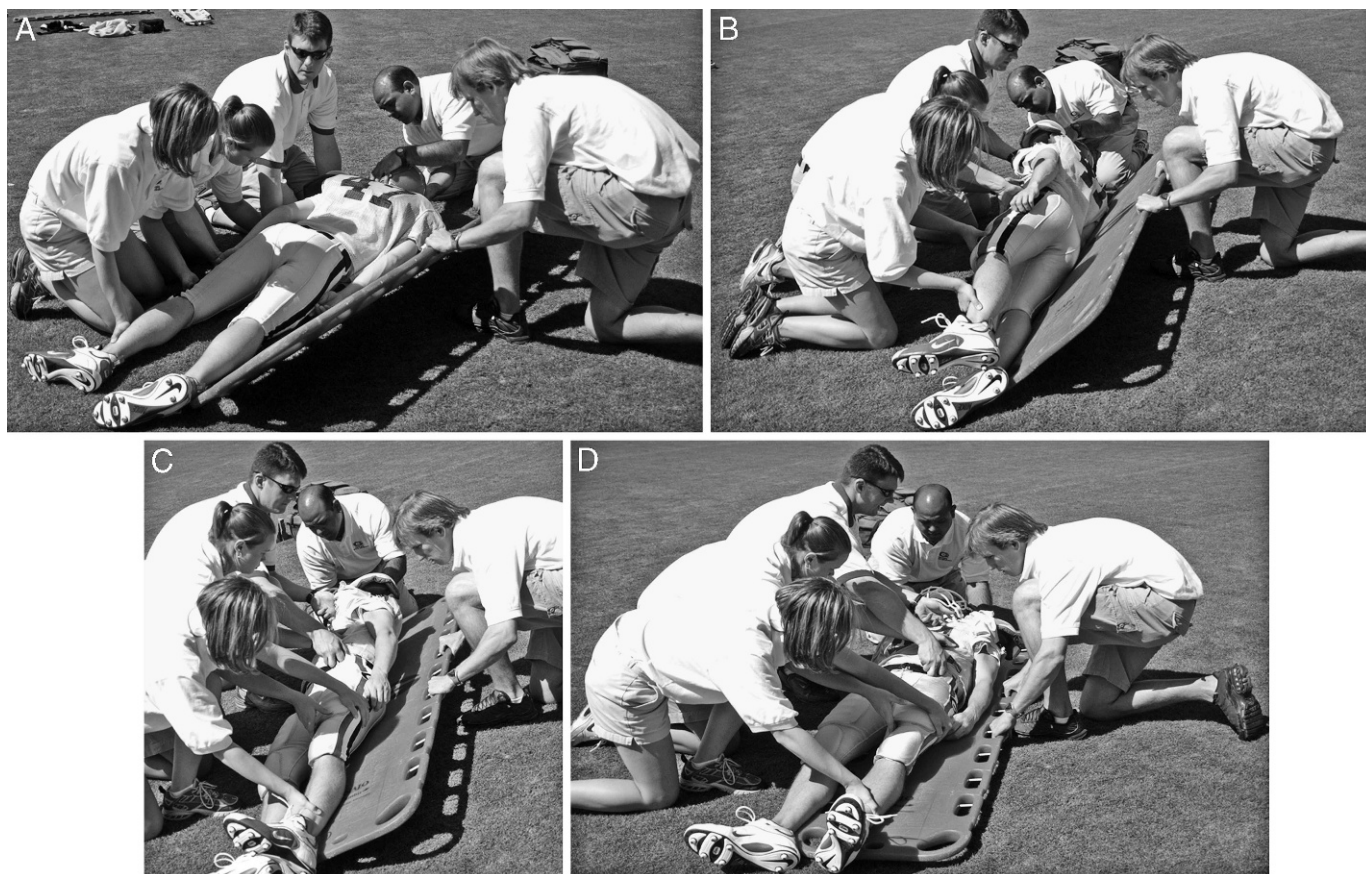


Figure 1. The prone log-roll push technique. **A**, Rescuer 1 provides cervical spine stabilization. Rescuers 2 through 4 are positioned on the side the athlete's head is facing. Rescuer 5 is on the opposite side, holding the spine board. **B**, Rescuers 2 through 4 reach across the athlete and, on command from rescuer 1, carefully roll the athlete away from them by pushing toward rescuer 5, who positions the spine board at a 45° angle beneath the athlete. **C** and **D**, Rescuers 2 through 4 slowly lower the athlete as rescuer 5 controls the spine board.

An alternative lift technique may be used with 3 rescuers who straddle the athlete rather than lifting from the side; this is referred to as the straddle lift and slide. With the straddle lift and slide, rescuer 1 provides cervical spine stabilization. Three additional rescuers straddle the athlete, with rescuer 2 at the upper torso, rescuer 3 at the hips and pelvis, and rescuer 4 at the legs. On command from rescuer 1, rescuers 2 through 4 lift the athlete approximately 6 inches (15.24 cm) off the ground while rescuer 5 slides the spine board beneath the athlete. On command, rescuers 2 through 4 slowly lower the athlete onto the spine board. Throughout this process, rescuer 1 provides all commands while maintaining cervical spine immobilization.

Other Alternatives for Transfer and Spine Boarding

Another alternative that may be used for transfer or full-body immobilization is the scoop stretcher. A stretcher that is hinged on both ends and has telescoping arms may be used to “scoop” the athlete without having to log roll or lift him or her. As with the lift-and-slide technique, the scoop stretcher may only be used on athletes in the supine position. With the scoop stretcher, the rescuer in charge (rescuer 1) provides cervical spine stabilization. Two additional rescuers, rescuers 2 and 3, position the stretcher. Rescuers 2 and 3 first adjust the length of the stretcher to the athlete using the telescoping arms. Because the stretcher is hinged at both ends, 2 different techniques

may be used. Rescuers 2 and 3 may open both hinges, separating the stretcher into 2 sections. Rescuer 2 positions the stretcher from one side, carefully sliding the stretcher beneath the athlete, while rescuer 3 does the same from the other side. They then work together to align the hinges and reconnect the scoop stretcher. An alternate technique is to open only one hinge and spread the scoop stretcher open in the shape of a “V,” position the stretcher at one end of the athlete, and then carefully close it, sliding the stretcher beneath the athlete and reconnecting the open hinge. The athlete may be secured to the scoop stretcher itself or, once the athlete is on the scoop stretcher, the lift-and-slide technique may be used. Rescuers raise the stretcher as a unit from both sides and slide a spine board beneath the scoop stretcher. The athlete may then be secured to the spine board. When using the scoop stretcher, rescuers should be aware that it may be difficult to close and secure the hinge at the top of the stretcher without interfering with rescuer 1's maintenance of cervical spine stabilization. It may be necessary for a rescuer to assume cervical spine control from the front of the athlete for rescuer 1 to allow for the top hinge to be secured. Additionally, it may be difficult to close the hinge(s) on heavier athletes as a result of their weight or on athletes who are wearing protective gear, such as shoulder pads.

Another alternative used for transfer or spine boarding is vacuum immobilization. The vacuum-immobilization system is based upon the same principle as extremity vacuum splints.




Figure 2. The 6-plus-person lift. A, Rescuer 1 provides cervical spine stabilization. Rescuers 2 through 4 are positioned on one side at the shoulders and thorax, hips, and legs, respectively; rescuers 5 through 7 are positioned similarly on the other side. Rescuer 8 is at the athlete's feet with the spine board. B, On command from rescuer 1, rescuers 2 through 7 lift the athlete approximately 6 inches off the ground, while rescuer 8 slides the spine board beneath the athlete. C, Rescuers 2 through 7 slowly lower the athlete onto the spine board.

Originally developed in Europe, the vacuum-immobilization systems for the spine are now available in the United States. The system is composed of a large nylon shell filled with tiny Styrofoam (The Dow Chemical Co, Midland, MI) beads. The system is spread out flat, and an air pump is used to withdraw air from the shell, making it semirigid. The athlete is then placed on the system, using either the log-roll or lift-and-slide technique. Air is pumped into the shell and the system conforms to the athlete. Then air is again withdrawn, creating a custom, form-fitted, full-body splint. Straps are built into the system to secure the athlete. An advantage of the vacuum-immobilization system is athlete comfort,⁷¹ as a result of the softness of the Styrofoam bead shell and the custom fit, which protects areas of bony prominence (eg, scapula, pelvis) that may develop pain and ischemic injury from prolonged compression on a hard surface, such as a standard spine board. The system also provides support to contour areas, such as the lumbar spine, buttocks, and popliteal fossa. Disadvantages are the size of the system, which renders it cumbersome, and the semirigidity of the system. The lift-and-slide technique may be better suited for the vacuum-immobilization system's semirigidity; however, the large size of the system may make it difficult to slide between the rescuers on either side.

Another technique that may be used for transfer or spine boarding is a short-board system such as the Kendrick Extrication Device (KED; Ferno, Wilmington, OH). Traditionally used by emergency medical services personnel for vehicle extrication, the short board may be placed

on a patient who is seated or has a flexed trunk. This technique may be useful in immobilizing athletes positioned awkwardly or where equipment barriers exist, such as in the gymnastics pit or pole-vault pit. A systematic review of prehospital spinal immobilization by Kwan and Bunn¹⁶⁵ showed a reduction in motion reported with the short-board technique compared with cervical-collar immobilization. With the short-board technique, rescuer 1 stabilizes the cervical spine from the front of the patient while rescuer 2 positions the short board behind the patient. Straps are used to secure the short board to the patient's chest, abdomen, and hip, and the last straps, with or without tape, secure the head to the board. Once immobilized with the short board, the patient may be extricated and then placed on and secured to a long spine board.

REPOSITIONING AFTER TRANSFER TO THE SPINE BOARD

In many cases, the athlete's position on the spine board after the initial spine-boarding procedure may not be ideal for securing him or her appropriately, particularly when using the log-roll technique. Therefore, it may be necessary to reposition the athlete to assure proper placement. After the initial spine-board placement, rescuer 1 assesses the athlete's overall position on the spine board. The athlete should never be moved perpendicular to the long axis of the board to avoid shearing and the possibility of spinal column movement. Instead, the athlete should be moved



Figure 3. Repositioning after transfer to the spine board. A, Rescuer 1 provides cervical spine stabilization. B, The other rescuers straddle the athlete and C, slide the athlete into position on command.

cephalad or caudad at an angle, depending on his or her position on the spine board. When repositioning, rescuer 1 provides specific commands: “On the count of 3, we are going to slide the athlete up and to the right ... ready ... 1 ... 2 ... 3.” The rescuers sliding the athlete may either straddle the athlete (Figure 3) or position themselves on both sides and slide from the sides. Throughout this process, rescuer 1 provides all commands while maintaining cervical spine immobilization.

Head Immobilization

A variety of head-immobilization options are available for securing the athlete to a spine board, including commercial devices, contoured helmet blocks, foam blocks, and towel rolls. Although once used extensively, sand bags are no longer recommended as head-immobilization devices because of their weight. If the spine board must be turned on its side, the sand bags will move the head laterally, compromising the cervical spine. Rescuers should select the head-immobilization technique with which they are most comfortable and be skilled in the use of that particular technique. *The head should always be the last part secured to the spine board.* Once the selected head-immobilization device stabilizes the head, either tape or hook-and-loop straps secure the head to the spine board. Two separate points of contact at the chin and the forehead⁷⁸ should be secured to prevent as much head and neck motion as possible. The tape or strap at the forehead should be placed at the level of the eyebrows to avoid slipping off the rounded top of the head. When using tape to secure the forehead, the rescuer applies the tape circumferentially for additional stability. The rescuer tears off a strip of tape approximately 4 ft (1.22 m) in length and “shimmies” the tape beneath the spine board, holding a tape end in each hand. One side of tape is pulled across the forehead at the level of the eyebrows, followed by the other side across the first piece (Figure 4). During this process, it may be necessary for a rescuer to assume cervical spine control from the front of the athlete for rescuer 1 to allow the head to be properly secured.

Types of Spine Boards and Full-Body Immobilization Devices

A variety of spine boards and full-body immobilization devices exist. The most commonly used device is the standard spine board. In the past, these boards were typically wood; however, most spine boards today are constructed of lighter fiberglass or a similar composite, offering increased strength and durability and easier cleaning, which is particularly important in light of bloodborne pathogens. Oversize spine boards to accommodate larger athletes should be considered based upon the athletic population being covered.

Rigid spine boards may be equipped with nonabsorbent padding. A patient strapped to spine boards may be restrained for several hours throughout the hospital emergency department evaluation and diagnostic testing process. Areas of bony prominence (eg, scapula, pelvis) may develop pain and ischemic injury from prolonged compression on a hard surface. Padding may help to reduce this, making the athlete more comfortable.

Most spine boards are the traditional rectangular shape and have cutouts that serve both as handles and sites to secure

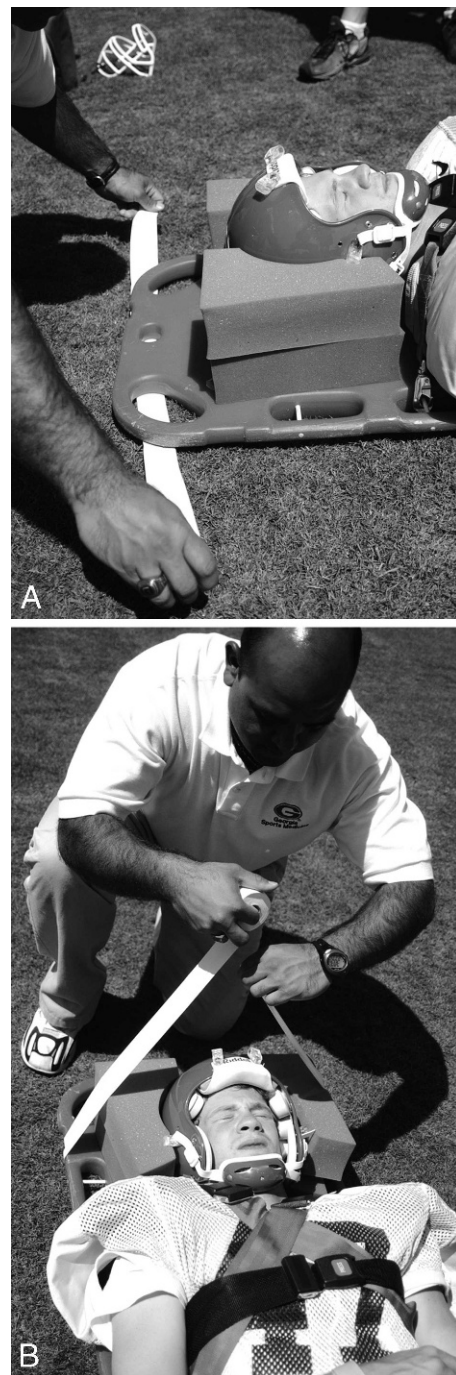


Figure 4. Head immobilization. A, Once the athlete is positioned properly, the rescuer “shimmies” a 4-ft (1.22-m) length of tape under the spine board. B, One side of the tape is pulled across the forehead at the level of the eyebrows, followed by the other side across the first piece.

straps. Some spine boards are contoured on the bottom with tapered edges to facilitate placing straps and hands into the cutouts, particularly when the spine board is on a soft surface, such as a grass field, on which the weight of the athlete can press the spine board into the ground (Figure 5).

Spine-Board Kit

Individuals responsible for the emergency care of athletes should prepare a spine-board kit to be maintained



Figure 5. Long spine-board handle designs. The board in the left hand has a beveled bottom, whereas the board in the right hand has recessed handles.

with the spine board. This kit should contain necessary supplies, such as a head-immobilization device, cervical collar, face-mask removal tools for sports in which helmets are worn (ideally on the rescuer's person during competition), straps to secure the athlete to the board, wrist straps to secure the athlete's hands together, tape, and various sizes of padding or toweling. In many cases, padding may be necessary for filling in gaps or spaces to maintain proper spinal column positioning.

Strapping Options and Techniques

Once the athlete is positioned on the spine board, securing with adequate strapping is essential to minimize excess movement during transport and transfers. A variety of strapping options exist, ranging from tape to the traditional 3-strap technique (chest, pelvis, and thighs), to spider straps to speed clips. When securing the athlete to the spine board, the arms should be kept free to facilitate a variety of diagnostic and treatment techniques. Once the torso is secured to the spine board, the hands may be placed together on top of the body using hook-and-loop wrist straps or tape.

In strapping the body to the spine board, the rescuers should use a technique to restrain the athlete as securely as possible. If the athlete vomits, which may occur with a closed head injury, the spine board may need to be turned to the side to allow airway clearance. Proper strapping will minimize lateral movement.

Rescuers should also consider strapping in terms of ambulance transport. With stopping and starting of the vehicle, the athlete may move axially or caudally on the board if not properly secured: such movement places additional stress on the cervical spine. To address this, 2 straps may be crossed in an "X" pattern below one axilla and across the body above the opposite shoulder; the process is repeated on the other side. Additionally, specifically placed strapping should be added to the torso to reduce lateral motion on a backboard.¹⁶⁶ A 7-strap system provides excellent stabilization on the spine board:

Straps 1 and 2: "X" at the chest and run across the shoulders

Strap 3: across chest
Straps 4 and 5: "X" across pelvis
Strap 6: across mid-thighs
Strap 7: across mid-lower legs

MANAGING THE COMBATIVE ATHLETE

As a result of the mechanism of injury, some athletes with cervical spine injuries may have concurrent closed head injuries. In this situation, rescuers may encounter a combative athlete who resists immobilization techniques, whether consciously or reflexively. This creates a problem for the rescuers, who should be aware that attempts to manually restrain a patient's head against his or her will may increase the stresses placed upon the patient's cervical spine. Rescuers should attempt to calm the patient and minimize movement as much as possible based upon the individual circumstances.

Appendix B. Clinical Considerations in the Management Protocol for the Equipment-Laden Athlete With a Spine Injury

FACE-MASK REMOVAL

Combined-Tool Approach

In equipment-laden sports, the face mask is secured to the helmet via loop straps that are screwed into the shell of the helmet with a screw and T-nut configuration. This arrangement can vary in style or number both within and between different types of sports. When the face mask must be removed from the helmet, the tool and technique selected should be those that create the least head and neck motion, are the fastest and easiest to use, and that impose the lowest chance of failure. For football helmets, authors have reported that a screwdriver, or cordless screwdriver, is faster,^{86,144,145} easier to use,⁸⁶ and creates less torque¹⁴⁵ and motion⁸⁶ at the head than many of the cutting tools commonly used to remove the face mask. However, screw removal can fail, and problems with the helmet hardware (screws, T-nuts), such as corrosion and rust, can cause the screw face to shred, allowing the T-nut to spin with the screw while turning or even to become so rusted as to fuse the hardware pieces together, preventing them from turning at all.⁸⁵ Therefore, a combined-tool approach provides the rescuer the added security of using a backup cutting tool, but only when necessary.

In describing the combined-tool approach to face-mask removal, we use the example of a football helmet face mask that is attached with 4 separate loop-strap attachments. We refer to the loop-strap locations under the earholes as the left side and right side loop strap or screw locations and the loop straps located at the forehead as the left top and right top loop strap or screw locations.

1. First attempt face-mask removal using a screwdriver.
 - a. The 2 side loop straps should be removed first. The top loop straps are then removed. This order prevents the face mask from rotating down onto the athlete's face or throat. Once all the screws are withdrawn far enough that they are totally

removed from the T-nut holding the face mask in place on the underside of the helmet shell, the face mask is simply lifted away, usually with the loop straps still attached to the face mask.

- b. Placing pressure on the underside of the loop strap with the thumb of the other hand while unscrewing can assist in separating the screw from the T-nut (Figure 6).
 - c. If, when attempting to remove the screws from the helmet, 1 or more screws cannot be unscrewed, skip to the next screw until all screws that can successfully be unscrewed are removed.
2. Use a backup cutting tool to cut away any remaining loop strap(s) (Figure 7).
 - a. Ensure that the cutting tool chosen will successfully cut the loop straps of the helmets currently worn by the football team or teams being covered. Not all face-mask removal tools will remove all helmet or loop-strap combinations.⁸⁶ If the home-team athletic trainer is the primary caregiver for the visiting team, he or she should identify the equipment used by the visitors and have the appropriate removal tools available.
 - b. In some traditional helmets with standard loop straps, the face mask can be rotated to the side, leaving more of the loop strap exposed for easier access with the cutting tool. This technique will not work on all helmet models.
 - c. The proper technique for cutting loop straps should be used with the chosen removal tool. For example, the Trainers Angel removal tool differs significantly in its cutting mechanism from the FM Extractor. Removal tools often come with instructions for their use. These should be followed and the techniques practiced thoroughly.
 - d. Loop straps should be cut in such a way as to ensure that the face mask can easily be lifted away from the helmet without loop-strap remnants obstructing removal. Sometimes, more often with the top loop-strap locations, a complete-thickness cut can be made through the entire loop strap. In other cases, it may be necessary to cut a “window” in the loop strap to allow the face-mask bar to be easily extracted; depending on the type of loop strap, at least 2 cuts are required.
 - e. Practicing face-mask removal is extremely important if cutting loop straps will be the chosen approach, as removing loop straps from face masks using cutting tools can be a difficult skill to perform.⁸⁶

Fortunately, athletic trainers can do much to increase the chances that a screwdriver will be successful in removing a screw and the face mask from a helmet. Weather-related factors have less effect on successful face-mask removal using a screwdriver than other factors that are under human control.⁸⁵ With the use of corrosion-resistant hardware in the helmet, more regular equipment maintenance, and



Figure 6. Face-mask removal. Placing the thumb behind the top loop strap while unscrewing the screw allows the loop strap to be lifted away once the screw is separated from the T-nut on the underside of the helmet. Reprinted with permission from Gale SD, Decoster LC, Swartz EE. The combined tool approach for face mask removal during on-field conditions. *J Athl Train.* 2008;43(1):14–20.

annual reconditioning, the chances of all 4 screws being successfully removed from the helmet increase.

As helmet, face-mask, and tool designs change, so too may these recommendations. For example, a recently developed face-mask attachment system in football helmets incorporates quick-release loop-strap attachments. To remove the loop straps, the quick-release mechanism is triggered by using the appropriately sized, pointed end of a tool to depress a button, which detaches the T-nut from the inside of the helmet (Figure 8). With any current or future developments in equipment and design, the goal for face-mask removal will always be to perform the task in an efficient manner in order to protect the athlete as much as possible during the management process and to do no further harm.

HELMET AND SHOULDER-PAD REMOVAL

Removal of either the helmet or shoulder pads may be necessary when such equipment prevents access to the airway or chest for primary life-support measures. Equipment removal may also be necessary if the helmet and shoulder pads do not maintain neutral cervical spine or

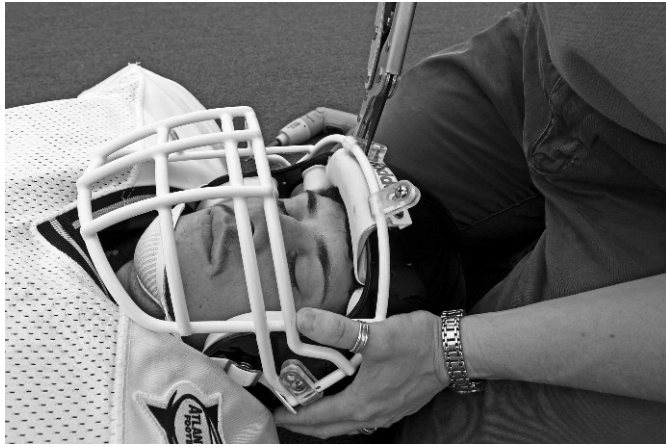

Figure 7. The backup cutting tool is used to cut away any remaining loop straps.

provide adequate immobilization of the head. Equipment design varies considerably, both among and within equipment-laden sports. This variability requires emergency responders to familiarize themselves with the nuances inherent in individual helmet and shoulder-pad models. The following are general guidelines offered to facilitate an approach to helmet and shoulder-pad removal.

1. The chin strap is removed from the helmet. Cutting away the chin strap is preferable to unsnapping it to avoid unnecessary movement.
2. Cheek pads should be removed from helmets if they interfere with the ability to remove the helmet from the head. Not all cheek pads in all types of helmets interfere with the ability to remove the helmet, so this

step can be skipped with certain helmets. However, whether this step is necessary should be determined in advance. The method for removing cheek pads may differ based upon the type of helmet:

- a. Some cheek pads are snapped into place and may be detached using a thin, rigid object, such as a tongue depressor, bite stick, or scissor tip.
 - b. Some cheek pads are secured with hook-and-loop straps and may also be removed by sliding a thin, rigid object between the strap sections.
 - c. Some cheek pads may require cutting with scissors for complete removal.
3. If the helmet contains air bladders, the air should be drained with a deflation needle or blade to loosen the fit of the helmet and facilitate removal.
 4. Before helmet removal, cervical spine stabilization should be transferred from the rescuer at the head to another rescuer, who assumes cervical spine control from the front. The rescuer at the head then grasps the helmet at the sides and gently removes it from the athlete. Slightly spreading the helmet from the sides and rotating the helmet up while sliding it off the head may facilitate removal. However, these techniques should be practiced in advance to ensure they enhance, rather than inhibit, helmet removal (Figure 9).
 5. Once the helmet is removed, a cervical collar is placed on the athlete before the shoulder pads are removed. Padding may also need to be placed underneath the head to avoid dropping the head and cervical spine into extension.





Figure 8. Quick-release loop-strap attachments. A, The quick-release mechanism is triggered by depressing the button. B, The T-nut is then detached from the inside of the helmet.

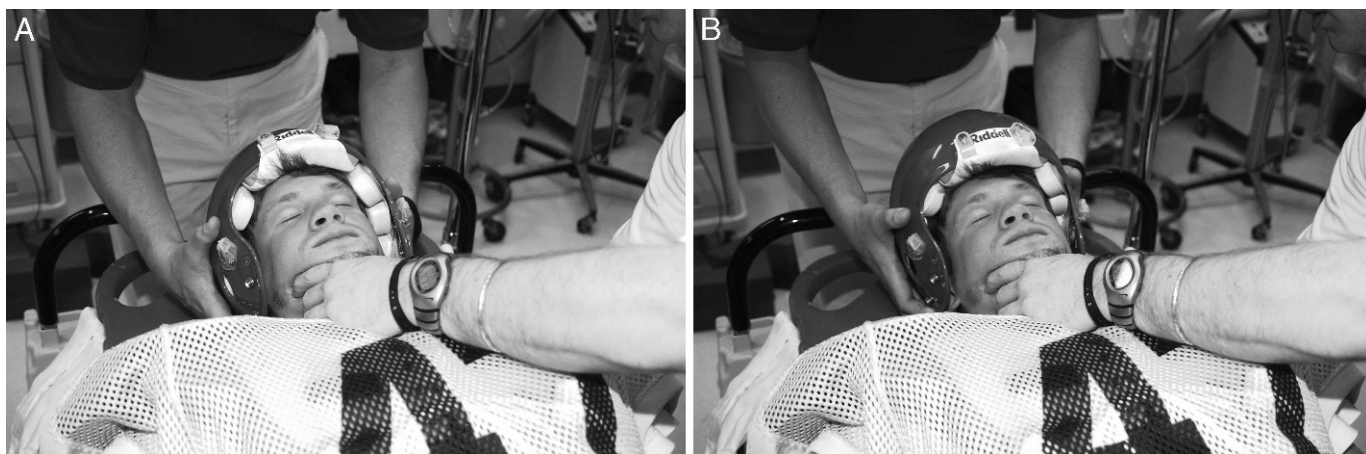


Figure 9. Helmet removal. A, Cervical spine stabilization is transferred from the rescuer at the athlete's head to another rescuer, who assumes control from the front. The rescuer at the head grasps the helmet at its sides and B and C, gently removes it from the athlete.

6. Any uniform top or jersey worn over the shoulder pads should be cut away before removing them. Using scissors, cut along the midline of the jersey, as well as out through each sleeve.
7. Cut through the strings or disconnect or cut through the plastic buckles in front of the shoulder pads.
8. Be aware of additional equipment that may be secured to the shoulder pads, such as rib pads or collars.
9. Remove the shoulder pads using one of the following techniques or a suitable alternative:
 - a. A standard technique requires transfer of cervical spine control from the rescuer at the head to another rescuer, who assumes cervical spine control from the front. The rescuer at the head then carefully removes the shoulder pads by sliding them out from under the athlete.
 - b. An alternative technique requires cutting the shoulder pads in the front and, if possible, in the back to split the pads into 2 sections. This technique does not require the helmet to be removed first but must be planned in advance, so that the cut in the back of the shoulder pads can be made during a log-roll maneuver. Once both sections of pads have been cut, simply pull apart from the sides while the rescuer at the head maintains cervical spine stabilization.

Address correspondence to National Athletic Trainers' Association, Communications Department, 2952 Stemmons Freeway, Dallas, TX 75247.